

# Protective Effect of Hesperidin against Cyclophosphamide Hepatotoxicity in Rats

Amr A. Fouad, Waleed H. Albuali, Iyad Jresat

**Abstract**—The protective effect of hesperidin was investigated in rats exposed to liver injury induced by a single intraperitoneal injection of cyclophosphamide (CYP) at a dose of 150 mg kg<sup>-1</sup>. Hesperidin treatment (100 mg kg<sup>-1</sup>/day, orally) was applied for seven days, starting five days before CYP administration. Hesperidin significantly decreased the CYP-induced elevations of serum alanine aminotransferase, and hepatic malondialdehyde and myeloperoxidase activity, significantly prevented the depletion of hepatic glutathione peroxidase activity resulted from CYP administration. Also, hesperidin ameliorated the CYP-induced liver tissue injury observed by histopathological examination. In addition, hesperidin decreased the CYP-induced expression of inducible nitric oxide synthase, tumor necrosis factor- $\alpha$ , cyclooxygenase-2, Fas ligand, and caspase-9 in liver tissue. It was concluded that hesperidin may represent a potential candidate to protect against CYP-induced hepatotoxicity.

**Keywords**—Cyclophosphamide, hesperidin, liver, rats.

## I. INTRODUCTION

CYCLOPHOSPHAMIDE (CYP) is a cytotoxic alkylating agent belonging to the class of nitrogen mustard compounds. CYP is commonly used in treatment of various types of cancers, and as an immunosuppressive agent in cases of organ transplantation and autoimmune diseases [1]. However, its usefulness is often limited by a wide range of adverse effects, including hepatotoxicity, which causes severe morbidity and may be fatal [2]. The exact mechanisms underlying CPY-induced hepatotoxicity are not well elucidated. Growing evidence suggests that oxidative stress, nitrosative stress, and intense inflammatory reactions play a crucial role [3], [4]. Also, antioxidants and anti-inflammatory agents were proved effective in attenuating CYP hepatotoxicity [5], [6].

Hesperidin is a natural bioflavonoid compound obtained from citrus fruits. Hesperidin possesses marked antioxidant and anti-inflammatory effects [7], [8]. Recent studies showed that hesperidin significantly protected against hepatotoxicity induced by lipopolysaccharide [9], cadmium [10], acetaminophen [11], and carbon tetrachloride [12] in rats. Hesperidin also protected against oxidative stress of tert-butyl

Amr A. Fouad is with the Department of Biomedical Sciences, Pharmacology Division, College of Medicine, King Faisal University, Al-Ahsa, Saudi Arabia (Primary address: Department of Pharmacology, Faculty of Medicine, Minia University, El-Minia, Egypt; phone: +966501776517; e-mail: amrfouad65@yahoo.com).

Waleed H. Albuali is with the Department of Pediatrics, College of Medicine, King Faisal University, Al-Ahsa, Saudi Arabia.

Iyad Jresat is with the Department of Biomedical Sciences, Pathology Division, College of Medicine, King Faisal University, Al-Ahsa, Saudi Arabia.

hydroperoxide in human hepatocytes [13]. However, to the best of our knowledge, this is the first study to investigate the protective effect of hesperidin against CYP-induced liver toxicity.

## II. MATERIALS AND METHODS

### A. Drugs and Chemicals

Hesperidin powder and CYP powder were purchased from Sigma-Aldrich, USA. Hesperidine was prepared in 0.5% aqueous solution of carboxymethylcellulose, and CYP was dissolved in normal saline. The doses of CYP and hesperidine used in the present study were selected based on our preliminary experiments and in accordance with previous reports [4], [11].

### B. Animals and Treatments

Male Sprague-Dawley rats, weighing 200  $\pm$  10 g were obtained from the Animal House, King Faisal University. The animals were housed at standard facilities (24  $\pm$  1°C, 45  $\pm$  5% humidity, and 12 h light-12 h dark cycle), supplied with standard laboratory chow and water *ad libitum*, and left to acclimatize for one week before the experiments. Experimental procedures were done in accordance with international guidelines for care and use of laboratory animals. The rats were randomly allocated to three groups (n = 8, each). The first (control) group received a single intraperitoneal injection of normal saline (vehicle of CYP). The rats of the second and third groups received a single intraperitoneal injection of CYP (150 mg kg<sup>-1</sup>). The animals of the second and third groups received the vehicle of hesperidine or hesperidin (100 mg kg<sup>-1</sup>/day, orally), respectively, for seven days starting five days before CYP administration.

### C. Sample Preparation and Biochemical Analysis

The rats were euthanized 24 h following CYP administration. Blood samples were collected through a puncture in the left ventricle, left for 60 min to clot, and centrifuged for 10 min at 5000 rpm. The obtained clear sera were stored at - 80°C and subsequently serum alanine aminotransferase (ALT) level was measured using a colorimetric assay kit following the manufacturer's instructions (Biodiagnostic, Egypt).

The liver of each animal was homogenized in cold potassium phosphate buffer (0.05 M, pH 7.4). The liver homogenates were centrifuged at 5000 rpm for 10 min at 4°C. Subsequently, colorimetric assay kits were used according to the recommendations of the manufacturer for determination of malondialdehyde (MDA), as an indicator of lipid peroxidation,

and glutathione peroxidase (GPx) activity (Biodiagnostic, Egypt), and myeloperoxidase (MPO) activity (BioVision, Inc., USA) in the supernatant of liver homogenates.

#### D. Histopathological Examination

Parts of the liver tissue of each animal were fixed in 10% formalin solution, dehydrated in ascending grades of ethanol and embedded in paraffin. Sections at 4- $\mu$ m were stained with hematoxylin and eosin (H&E), and examined under light microscope.

#### E. Immunohistochemical Examinations

Four  $\mu$ m thick sections were deparaffinised, rehydrated, and endogenous peroxidase activity was blocked with 3% H<sub>2</sub>O<sub>2</sub> in methanol. Sections were pre-treated in citrate buffer (pH 6.0), and were incubated with rabbit polyclonal anti-inducible nitric oxide synthase (iNOS), cyclooxygenase-2 (COX-2), Fas ligand (FasL), and anti-caspase-9 antibodies (Thermo Scientific, USA, dilution 1:100), and anti-tumor necrosis factor- $\alpha$  (TNF- $\alpha$ ) antibody (US Biological, USA, dilution 1:500). The sections were incubated with biotinylated goat anti-polyvalent, then with streptavidin peroxidase and finally with diaminobenzidine plus chromogen. Slides were counterstained with hematoxylin, and were visualized under light microscope.

#### F. Statistical Analysis

The data are expressed as mean  $\pm$  S.E.M. The results were analyzed by one-way analysis of variance (ANOVA) followed by Tukey test for post hoc comparisons using SPSS for Windows (version 18).  $P < 0.05$  was selected as the criterion for statistical significance.

### III. RESULTS

Administration of a single intraperitoneal injection of CYP at a dose of 150 mg kg<sup>-1</sup> caused significant increases of serum ALT, and hepatic MDA, and MPO activity, and a significant decrease in hepatic GPx activity as compared to control group. However, hesperidin-treated rats (100 mg kg<sup>-1</sup>/day, orally, for seven consecutive days, starting five days before CYP administration) showed significantly lower serum ALT, and hepatic MDA, and significantly higher hepatic GPx as compared to CYP group non-treated with hesperidin (Fig. 1). Also, Fig. 2 shows that CYP caused widespread damage, coagulative necrosis of the liver cells, associated with venous and sinusoidal dilatation and congestion. However, hesperidin markedly ameliorated the CYP-induced liver damage and maintained a histological picture similar to that of the control group.

In addition, increased expression of iNOS, TNF- $\alpha$ , COX-2, FasL, and caspase-9 in the hepatocytes was observed in rats received CYP without hesperidin treatment as compared to the control animals. On the other hand, hesperidin caused marked reduction of the CYP-induced expression of iNOS, TNF- $\alpha$ , COX-2, FasL, and caspase-9 in the liver tissue as compared to vehicle plus CYP group (Figs. 3-7).

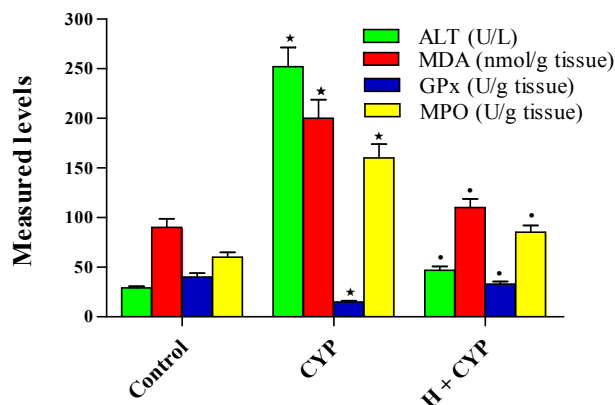


Fig. 1 Effects of hesperidin (H) on serum ALT, hepatic MDA, GPx and MPO activities in rats exposed to cyclophosphamide (CYP) hepatotoxicity. The data are expressed as mean  $\pm$  S.E.M. n = 8 in each group. \* $P < 0.05$  vs. control group, \* $P < 0.05$  vs. CYP group

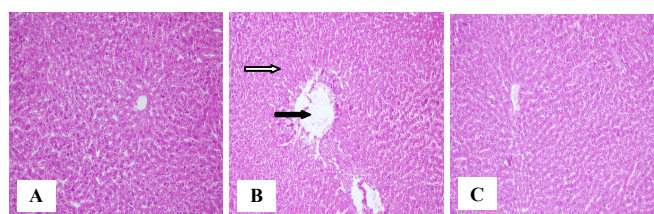


Fig. 2 Photomicrographs of rat liver (H&E, 200 $\times$ ). (A) control showing normal liver architecture; (B) CYP showing widespread damage, coagulative necrosis (white arrow), sinusoidal and venous dilatation and congestion (black arrow); (C) hesperidin plus CYP showing a histological picture comparable to that of the control

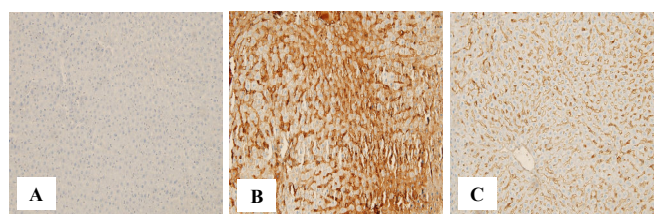


Fig. 3 Immunohistochemistry (200 $\times$ ) of iNOS in rat liver. (A) control showing no expression; (B) CYP showing a marked increase in immunoreactivity in the hepatocytes in brown color; (C) hesperidin plus CYP showing an obvious decrease in immunostaining

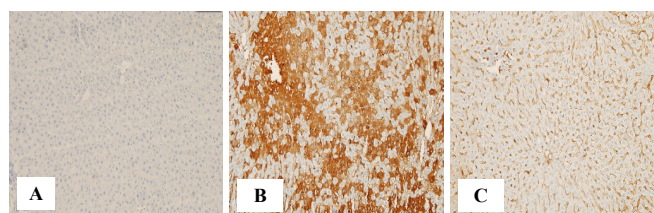


Fig. 4 Immunohistochemical staining (200 $\times$ ) of TNF- $\alpha$  in rat liver. (A) control showing no expression; (B) CYP showing a marked increase in immunoreactivity in the hepatocytes in brown color; (C) hesperidin plus CYP showing a decrease in immunostaining

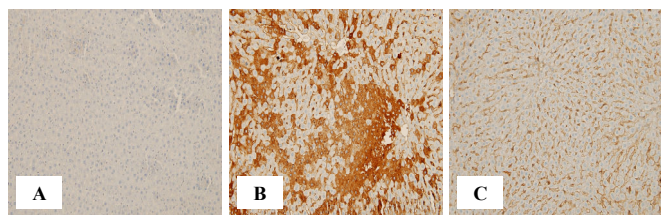


Fig. 5 Immunohistochemical staining (200 $\times$ ) of COX-2 in rat liver; (A) control showing no expression; (B) CYP showing a marked increase in immunoreactivity in the hepatocytes in brown color; (C) hesperidin plus CYP showing an obvious decrease in immunostaining

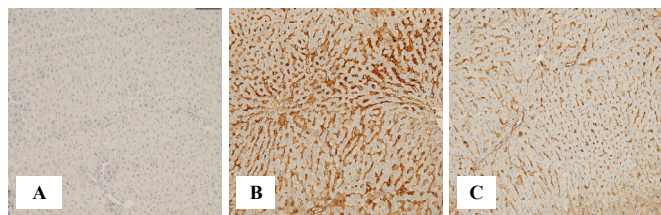


Fig. 6 Immunohistochemical staining (200 $\times$ ) of FasL in rat liver; (A) control showing no expression; (B) CYP showing a marked increase in immunoreactivity in the hepatocytes in brown color; (C) hesperidin plus CYP showing an obvious decrease in immunostaining

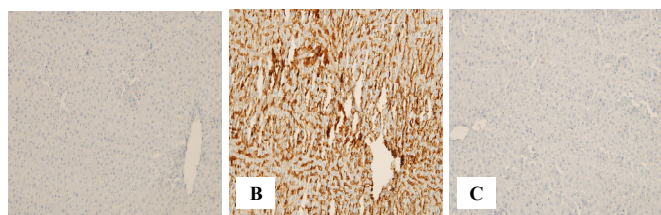


Fig. 7 Immunohistochemical staining (200 $\times$ ) of caspase-9 in rat liver; (A) control showing no expression; (B) CYP showing a marked increase in immunoreactivity in the hepatocytes in brown color; (C) hesperidin plus CYP showing an obvious decrease in immunostaining

#### IV. CONCLUSION

The present work confirmed that oxidative stress, increased lipid peroxidation, depletion of antioxidant defenses, and increased inflammatory responses are implicated in the pathogenesis of CYP-induced liver injury. In addition, it has been demonstrated that increased NO is involved in the pathogenesis of CYP-induced hepatotoxicity [14]. This can be explained by the ability of TNF- $\alpha$  to cause an up-regulation of iNOS enzyme which catalyzes the production of large amounts of nitric oxide which reacts with superoxide anion to generate peroxynitrite radical that causes further cell damage by nitrating cellular proteins and macromolecules [15]. Also, excess nitric oxide depletes intracellular reduced glutathione increasing the susceptibility to oxidative stress [16].

Hesperidin, the main active constituent isolated from citrus fruits, exerts marked antioxidant activity, scavenges reactive oxygen radicals, suppresses lipid peroxidation, and maintains the antioxidant defense mechanisms during free radical reactions [7], [8]. Also, hesperidin inhibits iNOS activity and decreases NO production, and therefore prevents nitrosative tissue stress [17]. In addition, hesperidin exhibits significant anti-inflammatory activity because it reduces the release of

inflammatory cytokines, and inhibits COX-2 the inducible form of cyclooxygenases thus decreasing the production of inflammatory prostaglandins [18]. Hesperidin also reduces hepatic MPO activity which is a good indicator for neutrophil infiltration and tissue inflammation which supports the anti-inflammatory action of hesperidin [19]. It was also revealed that hesperidin decreased the CYP-induced expression of FasL and caspase-9, involved in cell apoptosis. This is in agreement with previous studies which showed that hesperidin provided a significant anti-apoptotic effect by inhibiting caspase-9 activity [20]. However, the inhibitory effect of hesperidin on FasL expression was not assessed in previous studies. Therefore, it could be stated that hesperidin protected against CYP-induced liver cell apoptosis. The reduced FasL and caspase-9 activity observed with hesperidin treatment may be due to its free radical scavenging activity, and anti-inflammatory action.

The results of the present study indicate that hesperidin significantly ameliorated CYP-induced liver injury in rats. The antioxidant, anti-inflammatory, and anti-apoptotic activities of hesperidin can be considered the main factors which are responsible for the hepatoprotective effect. Therefore, hesperidin represents a potential therapeutic option to prevent hepatotoxicity induced by CYP.

#### REFERENCES

- [1] P. Perini, M. Calabrese, L. Rinaldi, P. Gallo, "The safety profile of cyclophosphamide in multiple sclerosis therapy," *Expert. Opin. Drug Saf.*, vol. 6, pp. 183-190, 2007.
- [2] M. Haubitz, "Acute and long-term toxicity of cyclophosphamide," *Transplantationsmedizin*, vol. 19, pp. S26-S31, 2007.
- [3] E. Selvakumar, C. Prahalathan, Y. Mythili, P. Varalakshmi, "Mitigation of oxidative stress in cyclophosphamide-challenged hepatic tissue by DL-alpha-lipoic acid," *Mol. Cell Biochem.*, vol. 272, pp. 179-185, 2005.
- [4] S. Jnaneshwari, M. Hemshekhar, M.S. Santhosh, K. Sunitha, R. Thushara, C. Thirunavukkarasu, K. Kemparaju, K.S. Girish, "Crocin, a dietary colorant, mitigates cyclophosphamide-induced organ toxicity by modulating antioxidant status and inflammatory cytokines," *J. Pharm. Pharmacol.*, vol. 65, pp. 604-614, 2013.
- [5] M. Zarei, T. Shivanandappa, "Amelioration of cyclophosphamide-induced hepatotoxicity by the root extract of *Decalepis hamiltonii* in mice," *Food Chem. Toxicol.*, vol. 57, pp. 179-184, 2013.
- [6] S. Nafees, S.T. Ahmad, W. Arjumand, S. Rashid, N. Ali, S. Sultana, "Modulatory effects of genisic acid against genotoxicity and hepatotoxicity induced by cyclophosphamide in Swiss albino mice," *J. Pharm. Pharmacol.*, vol. 64, pp. 259-267, 2012.
- [7] B.D. Sahu, M. Kuncha, G.J. Sindhura, R. Sistla, "Hesperidin attenuates cisplatin-induced acute renal injury by decreasing oxidative stress, inflammation and DNA damage," *Phytomedicine*, vol. 20, pp. 453-460, 2013.
- [8] D.I. Hamdan, M.F. Mahmoud, M. Wink, A.M. El-Shazly, "Effect of hesperidin and neohesperidin from bittersweet orange (*Citrus aurantium* var. *bigaradia*) peel on indomethacin-induced peptic ulcers in rats," *Environ. Toxicol. Pharmacol.*, vol. 37, pp. 907-915, 2014.
- [9] G. Kaur, N. Tirkey, K. Chopra, "Beneficial effect of hesperidin on lipopolysaccharide-induced hepatotoxicity," *Toxicology*, vol. 226, pp. 152-160, 2006.
- [10] L. Pari, K. Shagirtha, "Hesperetin protects against oxidative stress related hepatic dysfunction by cadmium in rats," *Exp. Toxicol. Pathol.*, vol. 64, pp. 513-520, 2012.
- [11] S.T. Ahmad, W. Arjumand, S. Nafees, A. Seth, N. Ali, S. Rashid, S. Sultana, "Hesperidin alleviates acetaminophen induced toxicity in Wistar rats by abrogation of oxidative stress, apoptosis and inflammation," *Toxicol. Lett.*, vol. 208, pp. 149-161, 2012.

- [12] Y.H. Yeh, Y.L. Hsieh, Y.T. Lee, "Effects of yam peel extract against carbon tetrachloride-induced hepatotoxicity in rats," *J. Agric. Food Chem.*, vol. 61, pp. 7387-7396, 2013.
- [13] M. Chen, H. Gu, Y. Ye, B. Lin, L. Sun, W. Deng, J. Zhang, J. Liu, "Protective effects of hesperidin against oxidative stress of tert-butyl hydroperoxide in human hepatocytes," *Food Chem. Toxicol.*, vol. 48, pp. 2980-2987, 2010.
- [14] A.A. El-Sheikh, R.A. Rifaai, "Peroxisome proliferator activator receptor (PPAR)- $\gamma$  ligand, but not PPAR- $\alpha$ , ameliorates cyclophosphamide-induced oxidative stress and inflammation in rat liver," *PPAR Res.*, vol. 2014, pp. 626319, 2014.
- [15] S.M. Morris, T.R. Billiar, "New insights into the regulation of inducible nitric oxide synthesis," *Am. J. Physiol.*, vol. 266, pp. E829-E839, 1994.
- [16] R.M. Clancy, S.B. Abramson, "Nitric oxide: a novel mediator of inflammation," *Proc. Soc. Exp. Biol. Med.*, vol. 210, pp. 93-101, 1995.
- [17] C. Acipayam, I. Bayram, K. Daglioglu, F. Doran, S. Yilmaz, G. Sezgin, B. Totan Ateş, A. Ozkan, A. Tanyeli, "The protective effect of hesperidin on methotrexate-induced intestinal epithelial damage in rats: an experimental study," *Med. Princ. Pract.*, vol. 23, pp. 45-52, 2014.
- [18] G. Saiprasad, P. Chitra, R. Manikandan, G. Sudhandiran, "Hesperidin alleviates oxidative stress and downregulates the expressions of proliferative and inflammatory markers in azoxymethane-induced experimental colon carcinogenesis in mice," *Inflamm. Res.*, vol. 62, pp. 425-440, 2013.
- [19] L. Xu, Z.L. Yang, P. Li, Y.Q. Zhou, "Modulating effect of hesperidin on experimental murine colitis induced by dextran sulfate sodium," *Phytomedicine*, vol. 16, pp. 989-995, 2009.
- [20] D.M. Wang, S.Q. Li, X.Y. Zhu, Y. Wang, W.L. Wu, X.J. Zhang, "Protective effects of hesperidin against amyloid- $\beta$  (A $\beta$ ) induced neurotoxicity through the voltage dependent anion channel 1 (VDAC1)-mediated mitochondrial apoptotic pathway in PC12 cells," *Neurochem. Res.*, vol. 38, pp. 1034-1044, 2013.