

Improved Lung Nodule Visualization on Chest Radiographs using Digital Filtering and Contrast Enhancement

Benjamin Y. M. Kwan and Hon Keung Kwan

Abstract—Early detection of lung cancer through chest radiography is a widely used method due to its relatively affordable cost. In this paper, an approach to improve lung nodule visualization on chest radiographs is presented. The approach makes use of linear phase high-frequency emphasis filter for digital filtering and histogram equalization for contrast enhancement to achieve improvements. Results obtained indicate that a filtered image can reveal sharper edges and provide more details. Also, contrast enhancement offers a way to further enhance the global (or local) visualization by equalizing the histogram of the pixel values within the whole image (or a region of interest). The work aims to improve lung nodule visualization of chest radiographs to aid detection of lung cancer which is currently the leading cause of cancer deaths worldwide.

Keywords—Chest radiographs, Contrast enhancement, Digital filtering, Lung nodule detection

I. INTRODUCTION

LUNG cancer is the leading cause of cancer deaths worldwide. According to the World Health Organization (WHO) [1], although one-year all-stage survival is reported to have increased from 32% in 1973 to 41% in 1994, five-year survival has remained unchanged at 14%. From the Canadian Lung Association [2] homepage, the Canadian Cancer Statistics 2009 reported that lung cancer causes approximately 29% among men and 22% among women of all cancer deaths. The American Lung Association [3] reports on its homepage that lung cancer is the most common cause of cancer death and it is the second-most commonly diagnosed cancer in both men and women. Current medical diagnostic imaging for lung cancer includes radiography, computed tomography (CT), and magnetic resonance imaging (MRI). Although the last two are more precise and accurate techniques, chest radiography is attractive for early detection due to its lower radiation dose, less invasive nature, and relatively affordable cost. CT and MRI are often used as a follow-up after a suspicious lung nodule has been detected through chest radiography. Therefore, chest radiography is likely to remain the common procedure for the early detection of lung cancer, which is crucial for improving survival rate.

B. Y. M. Kwan is with the Faculty of Medicine, University of Ottawa, 451 Smyth Road, Ottawa, Ontario, Canada K1H 8M5 (e-mail: bkwan066@uottawa.ca).

H. K. Kwan is with Department of Electrical and Computer Engineering, University of Windsor, 401 Sunset Avenue, Windsor, Ontario, Canada N9B 3P4 (e-mail: kwan1@uwindsor.ca).

Detection of lung nodules on chest radiographs can be challenging and missed due to a variety of factors including the presence of ribs, clavicle, trachea, blood vessels, and heart which could block or obscure the view of a nodule [4]. Also, suboptimal image acquisition and ill-defined margins compound the difficulty for radiological interpretations. Digital image processing offers various enhancement and detection techniques which could facilitate a more accurate detection of a lung nodule on a chest radiograph. In [5], a filtering method was introduced which combines the multi-scale-orientation of the direction scale Laplacian of Gaussian (LoG) filter and the multi-level of the morphological operators to effectively enhance lung nodules in chest radiograph while suppressing most of other anatomic structures, to facilitate detection. In [6], a local adaptive algorithm for image enhancement and denoising of digital X-rays images based on non-linear transformation of wavelet transform coefficients was introduced. The approach was observed to be more accurate over those of other conventional techniques. Estimation of pulmonary nodule location and size in CT scans is an important pre-processing step to determine the size and location of a region of interest. In [7], a LoG filtering method was used which shows an improved stability to changes in the seed point compared to that of a template-based method.

In this study, the focus is on digital filtering and contrast enhancement techniques which are to be used to improve the visibility of a chest radiograph and to make a lung nodule more evidently seen through reducing relative tonal background, sharper edges, and enhanced contrast. The study serves to facilitate early detection of a lung nodule from a chest radiograph as a pre-screening procedure.

II. METHODOLOGY

The approach first adopts linear phase digital filtering and then applies contrast enhancement to improve the visibility of a given chest radiograph to facilitate the selection of a region of interest (ROI) that may contain a suspicious lung nodule. The next step is to apply linear phase digital filtering and then contrast enhancement to the portion of the original chest image containing the ROI. To achieve a desirable performance, the gain and cutoff frequency of the digital filter are to be adjusted. To enhance the contrast of the filtered image or the filtered ROI, histogram equalization is to be applied.

The advantages of linear phase digital filtering in spatial domain on the whole or a selected ROI of a chest radiograph

include avoiding nonlinear phase distortion, and 2-dimensional square-shape and high-order filtering for effective reduction of the relative tonal background. By focusing on a ROI of a chest radiograph (instead of the whole chest radiograph), contrast enhancement can be carried out more effectively using the full dynamic range within a smaller set of pixels. Also, processing multiple regions of interest instead of a whole image saves computational time.

The types of chest radiographs adopted in this study contain nearly all its energy outside the passband of a 2-dimensional square-shape highpass digital filter with a normalized passband cutoff frequency of 0.01π radian per second. These dominant low-frequency components contain the background information of an image and without which the whole image will appear dark. Although the high-frequency components contribute a low level of energy, they contain the vital information on the structure and physical appearance of a lung image.

In this paper, the improvement strategy is to appropriately amplify the high-frequency components while keeping the low-frequency components at the same level. This can be achieved by using a 2-dimensional high-frequency emphasis digital filter $H(z_1^{-1}, z_2^{-1})$ constructed in separable form as defined by

$$H(z_1^{-1}, z_2^{-1}) = 1 + g^2 H_{HP}(z_1^{-1}) H_{HP}(z_2^{-1}) \quad (1)$$

In (1), $H_{HP}(z_1^{-1})$ and $H_{HP}(z_2^{-1})$ are two identical 1-dimensional $(N-1)$ th-order linear phase highpass digital filters to be applied respectively along the normalized frequencies w_1 and w_2 . For ease of explanation, the case of odd N and even symmetry FIR digital filter is considered. Each of the 1-dimensional highpass digital filters has a passband normalized passband cutoff frequency at 0.01π radian per second. A gain g with a value greater than unity is used in (1). As the value of g increases, a filtered image will contain sharper edges and more details.

III. DIGITAL FILTER DESIGN

In this section, a 1-dimensional $(N-1)$ th-order linear phase highpass digital filter $H_{HP}(z^{-1})$ is to be designed and used in (1). The transfer function of $H_{HP}(z^{-1})$ can be expressed as

$$H_{HP}(z^{-1}) = \left(h(0) + \sum_{n=1}^{(N-1)/2} [h(-n)z^n + h(n)z^{-n}] \right) \quad (2)$$

Due to even symmetry, the coefficients are related by

$$h(-n) = h(n) \text{ for } n = 0, 1, 2, \dots, (N-1)/2 \quad (3)$$

Substituting $z=e^{jwn}$ into (2)-(3), the frequency response of the digital filter is

$$H_{HP}(e^{-jwn}) = \left(h(0) + \sum_{n=1}^{(N-1)/2} [h(-n)e^{jwn} + h(n)e^{-jwn}] \right) = \sum_{n=0}^{(N-1)/2} t(n) \cos(nw) \quad (4)$$

The coefficients $t(n)$ are related to the coefficients $h(n)$ of (2)-(3) as

$$t(0) = h(0); t(n) = 2h(n) \text{ for } n = 1, 2, \dots, (N-1)/2 \quad (5)$$

In this paper, the $(N-1)$ th-order 1-dimensional linear phase FIR highpass digital filter $H_{HP}(z^{-1})$ is designed using the constrained least-squares method as described in [8] with specifications (w_p : normalized passband cutoff frequency; g : passband gain; δ_s : stopband upper maximum deviation; δ_p : passband upper and lower maximum deviations) as summarized in Table I. The magnitude responses (within 0 to 1 and in dB), group delay, and zero-plot of the designed 1-dimensional linear phase highpass digital filter are shown in Fig. 1. Fig. 2 shows the corresponding magnitude responses of the 2-dimensional high-frequency emphasis digital filter $H(z_1^{-1}, z_2^{-1})$ obtained as defined in (1).

TABLE I
 HIGHPASS DIGITAL FILTER SPECIFICATIONS

N	w_p	g	δ_s	δ_p
201	0.01π	3	0.01	± 0.01

IV. CONTRAST ENHANCEMENT

In a digital image, each $[x, y]$ pixel value represents the intensity value at the location $[x, y]$ of the image. The histogram of a digital image is a graphical representation of the intensity values that make up the image. The intensity values (for example, levels 0 to 4095 of a 12-bit image) are displayed along the x-axis of the graph whereas the frequency of occurrence of each of these intensity values in the image is shown on the y-axis. In general, the distribution of the intensity values of an image is non-uniform. For examples, there are images with backgrounds and foregrounds that are both bright or both dark such as for images that are over-exposed or under-exposed. For the case of X-ray images such as chest radiographs, their histograms typically have intensity values located mostly on the bright region (for dark is 0 format). In this paper, application of high-frequency emphasis digital filtering on the whole image (or a ROI) of a chest radiograph helps to reveal sharper edges and more details, and to spread out the histogram of its intensity values. However, the contrast of the whole filtered image (or within the filtered ROI) still has much room to be improved.

Histogram equalization is an image processing technique that can increase the contrast of a digital image by effectively spreading out the most frequently occurred intensity values through a nonlinear transformation function. This allows pixels in areas of lower contrast to gain a higher contrast.

Consequently, an enhanced view of individual details can be obtained. A key advantage of histogram equalization is that it involves a perfectly invertible and computationally simple transformation function. In this paper, applying histogram equalization on the whole image (or a ROI) of a high-frequency emphasis filtered chest radiograph is found to be a useful technique that can increase the global contrast (or the local contrast within a ROI) of the filtered chest radiograph that contains informative pixels represented by close intensity values.

V. SIMULATION RESULTS

Given a chest radiograph image I of sizes $M \times N$, the computational steps listed in Table II are performed:

TABLE II
 IMAGE ENHANCEMENT STEPS

Step	Description
1	Filter the image I using the high-frequency emphasis digital filter defined in (1) and designed using the specifications of Table I. The image I and the filtered image I_F are shown respectively in Figs. 3-4.
2	Apply contrast enhancement to the image I_F and the contrast enhanced filtered image I_{FC} is shown in Fig. 5.
3	Define a location $[x_c, y_c]$ from the image I_F or the image I_{FC} at which a suspicious lung nodule is centered. Define a ROI centered at $[x_c, y_c]$ and with a sufficient region $K \times L$ that contains the suspicious lung nodule and its surrounding area. The ROI image denoted by R is shown in Fig. 6.
4	Filter the image R using the high-frequency emphasis digital filter of Step 1. The filtered image is denoted by R_F and is shown in Fig. 7.
5	Apply contrast enhancement to the image R_F and the contrast enhanced filtered image R_{FC} is shown in Fig. 8.

In the simulations, chest radiograph images [9] of resolution 12-bit and sizes 2048×2048 ($=M \times N$) pixels were used. The origin of an image is located at the top left corner. In this paper, the image I (JPCLN014.img [9]) adopted contains a lung nodule at the location $[1634, 692]$ ($=[x_c, y_c]$). The sizes of the ROI image are 513×513 ($=K \times L$) with its center $[257, 257]$ corresponds to the location $[1634, 692]$ of the whole image I .

VI. CONCLUSION

In this paper, an approach for improved visualization of lung nodules on chest radiographs has been presented. The approach is based on an appropriate amplification of the high frequency components while preserving the low frequency tonal background. Results show that the approach can effectively improve the visibility of the whole image (or a specified ROI) to facilitate the early detection of the presence of a lung nodule and its diagnosis for further examination and treatment.

REFERENCES

[1] World Health Organization (WHO) (<http://www.who.int/en/>).
 [2] Canadian Lung Association (<http://www.lung.ca>).
 [3] American Lung Association (<http://www.lungusa.org/>).
 [4] J. H. M. Austin, B. M. Romney, and L. S. Goldsmith, "Missed bronchogenic carcinoma: Radiographic findings in 27 patients with a

potentially resectable lesion evident in retrospect," *Radiology*, vol. 182, pp. 115-122, January 1992.
 [5] Z. Shi, M. Zhao, L. He, and Y. Wang, "A combinational filtering method for enhancing suspicious structures in chest X-rays," *Journal of Information & Computational Science*, vol. 8, pp. 997-1005, July 2011.
 [6] H. Öktem, K. Egiazarian, J. Niittylahti, and J. Lemmetti, "An approach to adaptive enhancement of diagnostic X-ray images," *EURASIP Journal on Applied Signal Processing*, vol. 5, pp. 430-436, 2003.
 [7] A. C. Jirapatnakul, S. V. Fotin, A. P. Reeves, A. M. Biancardi, D. F. Yankelevitz, and C. I. Henschke, "Automated nodule location and size estimation using a multi-scale Laplacian of Gaussian filtering approach," in *Proceedings of 31st Annual International Conference of IEEE Engineering in Medicine and Biology Society*, Minneapolis, Minnesota, USA, 2-6 Sept. 2009, pp. 1028-1031.
 [8] I. W. Selesnick, M. Lang, and C.S. Burrus. "Constrained least square design of FIR filters without specified transition bands," *IEEE Transactions on Signal Processing*, vol. 44, no. 8, pp. 1879-1892, August 1996.
 [9] J. Shiraishi, S. Katsuragawa, J. Ikezoe, et al. "Development of a digital image database for chest radiographs with and without a lung nodule: Receiver operating characteristic analysis of radiologists' detection of pulmonary nodules," *American Journal of Roentgenology*, vol. 174, no. 1, pp. 71-74, January 2000.

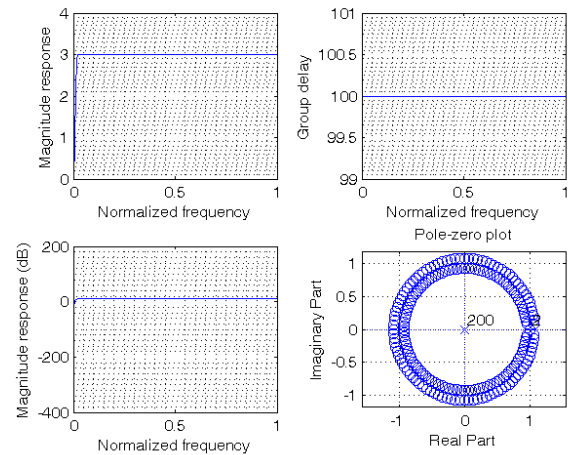


Fig. 1 Magnitude responses, group delay, and zero-plot of 1-dimensional 200th-order linear phase highpass digital filter

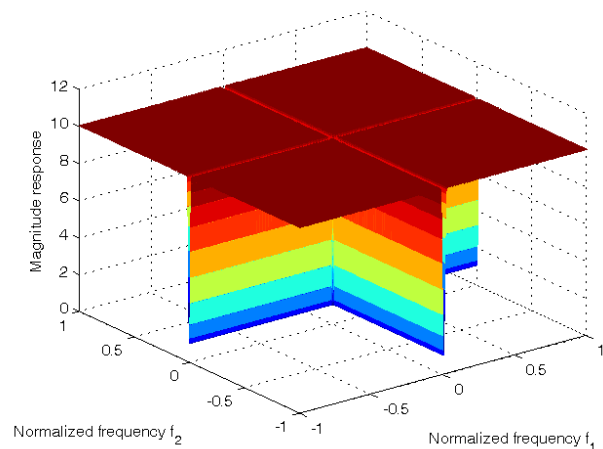


Fig. 2 Magnitude response of 2-dimensional linear phase high-frequency emphasis digital filter

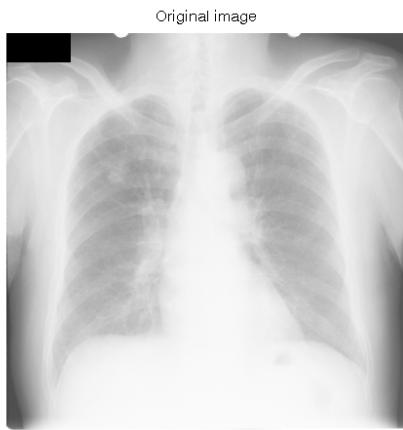

Fig. 3 Original 2048x2048 chest radiograph image I

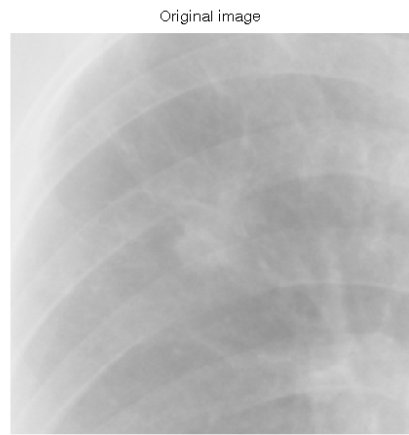


Fig. 6 The selected ROI image R

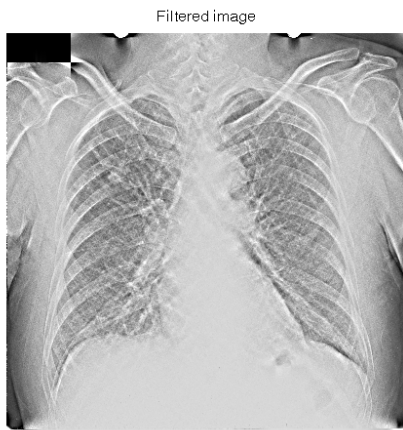


Fig. 4 High-frequency emphasis filtered image I_F

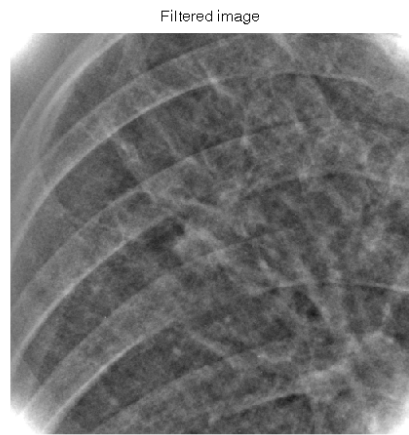


Fig. 7 High-frequency emphasis filtered ROI image R_F

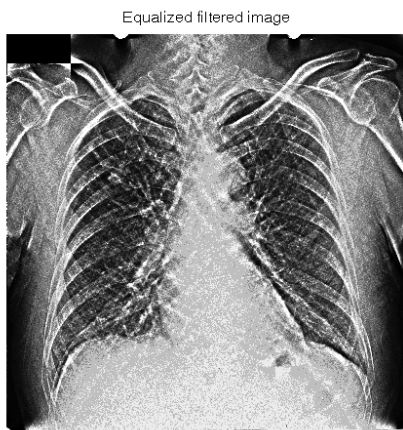


Fig. 5 Contrast enhanced filtered image I_{FC}

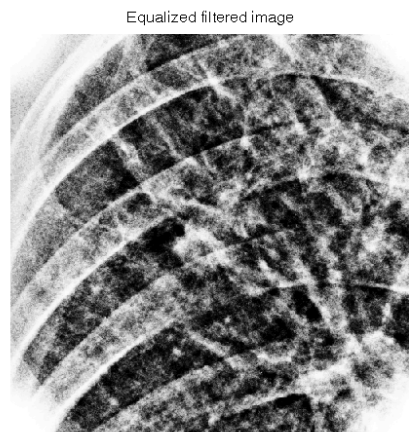


Fig. 8 Contrast enhanced filtered ROI image R_{FC}