

Segmental and Subsegmental Lung Vessel Segmentation in CTA Images

H. Özkan

Abstract—In this paper, a novel and fast algorithm for segmental and subsegmental lung vessel segmentation is introduced using Computed Tomography Angiography images. This process is quite important especially at the detection of pulmonary embolism, lung nodule, and interstitial lung disease. The applied method has been realized at five steps. At the first step, lung segmentation is achieved. At the second one, images are threshold and differences between the images are detected. At the third one, left and right lungs are gathered with the differences which are attained in the second step and Exact Lung Image (ELI) is achieved. At the fourth one, image, which is threshold for vessel, is gathered with the ELI. Lastly, identifying and segmentation of segmental and subsegmental lung vessel have been carried out thanks to image which is obtained in the fourth step. The performance of the applied method is found quite well for radiologists and it gives enough results to the surgeries medically.

Keywords—Computed tomography angiography (CTA), Computer aided detection (CAD), Lung segmentation, Lung vessel segmentation

I. INTRODUCTION

LUNG vessel segmentation in CTA images is a necessary prerequisite in various medical imaging applications, for instance; detection of pulmonary embolism [1-4], lung nodule [5,6], interstitial lung disease (ILD) [7-9], emphysema [10,11], and surgical planning. Furthermore, the vessel segmentation provides an equipment to understand the relation between vessels and diseases.

There are several approaches to segment vessel. Some of them; Buelow et. al. segmented the lung vessels using fast marching techniques [12]. Kiraly et al. applied a threshold operation to the lung areas for segmentation of lung vessels in contrast enhanced CT data [13]. Zhou et al. Lung vessel tree segmented by a threshold based region growing method from CT images without any contrast enhancement [14]. Masutani et al. used a propagation scheme based on bounded space mathematical morphology [15].

In this paper, a new CAD system for automatic segmentation of segmental and subsegmental lung vessel is developed in CTA images. This process was differently carried out from previous works. Before, lungs were segmented and then, segmental and subsegmental lung vessels were segmented with morphological methods. Data sets belonging to 33 patients were used. The results at the end of these processes have been analyzed by the performance measures which are used in medical image evaluation. The performance of the applied method is found quite well for radiologists.

II. MATERIALS AND METHODS

A. Data Retrieval

In this study, data was collected from Dr. Siyami Ersek thoracic and cardiovascular surgery training and research hospital. All pulmonary computed tomographic angiography exams performed with 16 detectors CT (Somatom Sensation 16, Siemens, AG, Erlanger, Germany) equipment. Patients were informed about the examination and also for breath holding. Imaging performed with Bolus tracking program. After scenogram, single slice is taken at the level of pulmonary truncus. A bolus tracking is placed at pulmonary truncus and trigger is adjusted to 100 HU (Hounsfield Unit). 70ml nonionic contrast agent at the rate of 4mL/sec with an automated syringe (Optistat Contrast Delivery System, Liebel-Flarsheim, USA) is used. When opacification is reached at the pre-adjusted level exam performed from the supraclavicular region to the diaphragms. Contrast injection performed via 18-20G intra venous cannula that was placed at antecubital vein. Scanning parameters were 120 kV, 80- 120 mA, slice thickness 1 mm, pitch 1.0-1.2. Images reconstructed with 1mm and 5mm thickness, and evaluated at mediastinal window (WW 300, WL 50) with advanced workstation (Wizard, Siemens, AG, Erlanger, Germany) in coronal sagittal and axial planes. Oblique plans used if needed. Each exam consists of 400-500 images with 512x512 resolutions.

B. Method

To segment minor lung vessels (segmental and subsegmental vessel), firstly, lung segmentation is obtained without vessels which continue toward the lung region from the Mediastinum Region (MR). Then, images are threshold and differences between the images are detected. The differences are segmental vessels which continue toward the lung region from the MR. After these processes, left and right lungs are gathered with the differences which are attained. Therefore, ELI is obtained and image, which is threshold for vessel, is gathered with the ELI. Label of segmental and subsegmental vessels are different from the other components in images which are attained. Lastly, segmental and subsegmental vessels are detected with the labels of them. The detailed follow chart of this method is shown in Fig. 1.

H. Özkan is with the University of Istanbul Kültür, Vocational Schools of Technical Sciences, in Istanbul, Turkey (h.ozkan@iku.edu.tr)

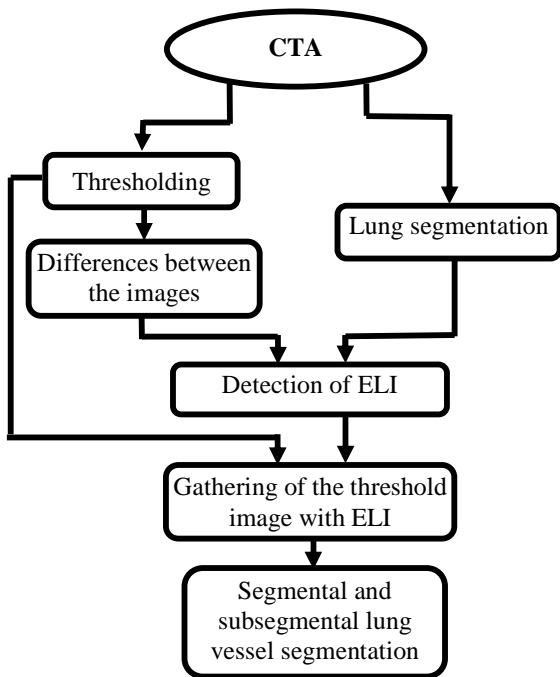


Fig. 1 The diagram of segmental and subsegmental vessel segmentation method

CTA images, which are in hands, are 400 as being 2D. Firstly, to segment lung, each image has been threshold using Image >-300 HU as the level of threshold. The small objects in lung region are removed by small object removal filters. Lastly, regions, outside of patient's body were removed and regions, inside of patient's body were determined as right and left lungs without vessels which continue toward the lung region from the MR. In Fig 2a, Original 2D image, in Fig 2b, left and right lungs are shown [16].

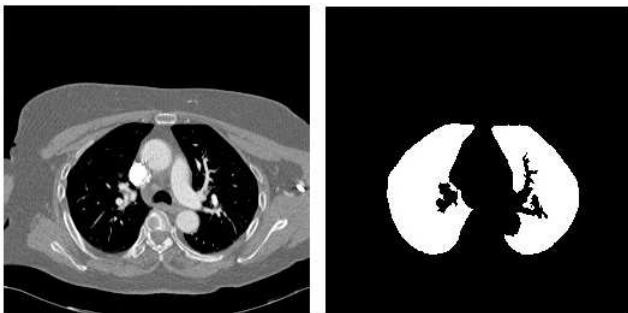


Fig. 2a) Original image b) Left and right lung

Segmental vessels continue toward the lung region from the MR. Secondly, differences of the first image which segmental vessel rise and the previous image which hasn't segmental vessel have been taken. The differences are determined as segmental vessel. Then, this process is used in the next images two by two. The difference image, which is attained, has been removed from the image whose the difference is taken in order to achieve the differences in next 2D images. In Fig 3a, 2D image which hasn't segmental vessels is shown, in Fig 3b, 2D image which has segmental vessels is shown.




Fig. 3a) 2D image without segmental vessels b) 2D image with segmental vessels

In Fig. 4, the difference image of the Fig 3b and the Fig 3a is shown.



Fig. 4 The difference image

Thirdly, left and right lungs in Fig. 2b are gathered with the differences which are attained in the second step in Fig 4. Therefore ELI is obtained (Fig. 5).



Fig. 5 Exact lung image

Fourthly, each image has been threshold using $1HU < Image < 500 HU$ as the level of threshold for vessels. In Fig. 6, 2D threshold image is shown.

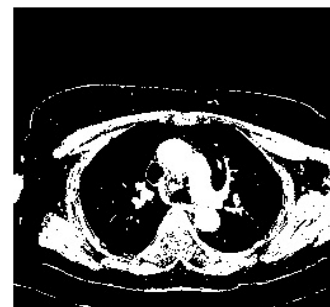


Fig. 6 Threshold image

Then, images, which are threshold for vessels in Fig. 6, are gathered with the ELI in Fig 5. The last image is shown in Fig. 7.

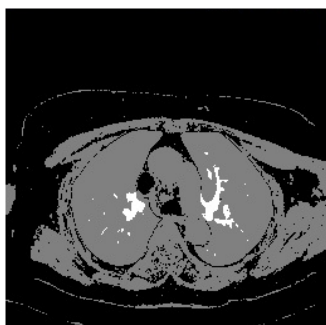


Fig. 7 Gathered image

In image which carried out at the end of gathering, label of segmental and subsegmental vessels are different from the other components. They are seen in white color because of its value of 2 and other components are seen in grey color because of their value of 1 (Fig. 7).

Lastly, segmental and subsegmental vessels are detected with the labels of them. Components, which have the value of 2, have been detected as segmental and subsegmental vessels and then they have been copied to a new image (Fig.8a). The last image of segmental and subsegmental vessel is logical. Therefore, the logical image is multiplied with original image (Fig.8b). Then segmental and subsegmental lung vessel segmentation is carried out with values of HU.

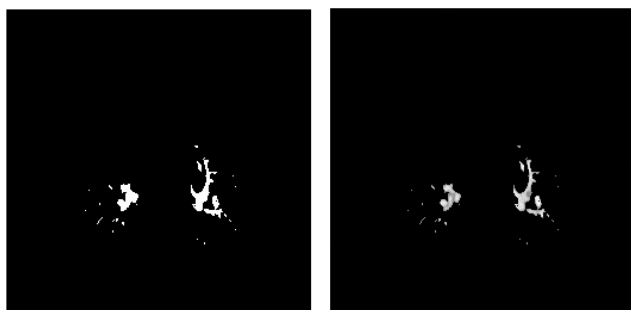


Fig. 8a) 2D logical segmental and subsegmental lung vessels b) 2D original segmental and subsegmental lung vessels

III. CONCLUSION AND DISCUSSION

In this paper, Lung vessel segmentation is differently carried out from previous works. The method, which has been tried at this work, applied to 33 different patients. Segmented lung vessel trees, which belong to each patient, are reviewed by radiologists and it has been seen that the results at the end of applied method adjust to segmental and subsegmental lung vessel determined with hand by the radiologists. With the help of this work, which performs segmental and subsegmental lung vessel segmentation in a fast way, detection of pulmonary embolism, lung nodule, interstitial lung disease or emphysema can be determined in a faster way.

ACKNOWLEDGMENT

The author would like to thank Assoc. Prof. Dr. Onur Osman and Assoc. Prof. Dr. Sinan Şahin. Besides, this work has been supported by Dr. Siyami Ersek Thoracic and Cardiovascular Surgery Training and Research Hospital, Istanbul, Turkey. The author wish to thank chief of staff in the hospital, Prof. Dr. Ibrahim Yekeler.

REFERENCES

- [1] A. Kiraly, "A comparison of 2D and 3-D evaluation methods for pulmonary embolism detection in CT images," in Proc. SPIE Med. Imag, 2006, vol. 6146.
- [2] E. Pichon, C. L. Novak, A. P. Kiraly, and D. P. Naidich, "A novel method for pulmonary emboli visualization from high-resolution CT images," in Proc. SPIE Med. Imag., 2004, vol. 5367, pp. 161–170.
- [3] Z. Maizlin, P. Vos, M. Gody, and P. Cooperberg, "Computer-aided detection of pulmonary embolism on CT angiography: Initial experience," in Proc. Annu. Meeting RSNA, 2006.
- [4] C. Zhou et al., "Computerized detection of pulmonary embolism in 3-D CT images: Vessel tracking and segmentation techniques," in Proc. SPIE Med. Imag., 2003, vol. 5032, pp. 1613–1620.
- [5] Özekes S, Osman O, Ucan O N, "Nodule Detection in the Lung Region, which is Segmented with Genetic Cellular Neural Networks, Using 3D Template Matching with Fuzzy Rule Based Thresholding", Korean Journal of Radiology, Vol.9, No.1, pp.1-9, 2008.
- [6] Özekes S, Osman O, "Computerized Lung Nodule Detection Using 3D Feature Extraction and Learning Based Algorithms", Journal of Medical Systems, Volume: 34 Issue: 2 Pages: 185-194, APR 2010.
- [7] Sluimer I, Waes P, Viergever M, and Ginneken B, "Computer-aided diagnosis in high resolution CT of the lungs", Med. Phys. 30, 3081–3090, 2003.
- [8] Uchiyama Y, Katsuragawa S, Abe H, Shiraishi J, Li F, Li Q, Zhang C, Suzuki K, and Doi K, "Quantitative computerized analysis of diffuse lung disease in high-resolution computed tomography", Med. Phys. 30, 2440–2454, 2003.
- [9] Uppaluri R, Hoffman E, Sonka M, Hartley P, "Hunninghake, and G. McLennan, "Computer recognition of regional lung disease patterns", Am. J. Respir. Crit. Care Med. 160, 648–654, 1999.
- [10] Xu Y, Sonka M, McLennan G, Guo J, and Hoffman E, "MDCTbased 3-D texture classification of emphysema and early smoking related lung pathologies", IEEE Trans. Med. Imaging 25, 464–475, 2006
- [11] Uppaluri R, Mitsa T, Sonka M, Hoffman E, and McLennan G, "Quantification of pulmonary emphysema from lung computed tomography images", Am. J. Respir. Crit. Care Med. 156, 248–254, 1997.
- [12] Buelow T, Wiemker R, Blaffert T, Lorenz C, and Renisch S, "Automatic extraction of the pulmonary artery tree from multi-slice CT data", in SPIE Medical Imaging, Apr. 2005, vol. 5746, pp. 730–740.
- [13] Kiraly A P, Pichon E, Naidich D P, and Novak C L, "Analysis of arterial subtrees affected by pulmonary emboli", in SPIE Medical Imaging, May 2004, vol. 5370, pp. 1720–1729.
- [14] Zhou X, Hayashi T, Hara T, Fujita H, Yokoyama R, Kiryu T, and Hoshi H, "Automatic segmentation and recognition of anatomical lung structures from high-resolution chest CT images", Computerized Medical Imaging and Graphics 30, pp. 299–313, 2006.
- [15] Masutani Y, Schiemann T, and Höhne K H, "Vascular shape segmentation and structure extraction using a shape-based region-growing model", In Medical Image Analysis and Computer Assisted Intervention (MICCAI), pages 1242–1249, October 1998.
- [16] Özkan H., Osman O., Şahin S., Atasoy M. M., Barutca H., Boz A.F., Olsun A., "Lung Segmentation Algorithm for CAD System in CTA Images" World Academy of science Engineering end Technology (ICBCBBE 2011), July 24- 26, 2011, Paris