

Influence of Calcium Intake Level to Osteoporotic Vertebral bone and Degenerated Disc in Biomechanical Study

Dae Gon Woo, Ji Hyung Park, Chi Hoon Kim, Tae Woo Lee, Beob Yi Lee, Han Sung Kim

Abstract—The aim of the present study is to analyze the generation of osteoporotic vertebral bone induced by lack of calcium during growth period and analyze its effects for disc degeneration, based on biomechanical and histomorphometrical study.

Mechanical and histomorphological characteristics of lumbar vertebral bones and discs of rats with calcium free diet (CFD) were detected and tracked by using high resolution in-vivo micro-computed tomography (in-vivo micro-CT), finite element (FE) and histological analysis. Twenty female Sprague-Dawley rats (6 weeks old, approximate weight 170g) were randomly divided into two groups (CFD group: 10, NOR group: 10). The CFD group was maintained on a refined calcium-controlled semisynthetic diet without added calcium, to induce osteoporosis. All lumbar (L1-L6) were scanned by using in vivo micro-CT with 35 μ m resolution at 0, 4, 8 weeks to track the effects of CFD on the generation of osteoporosis.

The findings of the present study indicated that calcium insufficiency was the main factor in the generation of osteoporosis and it induced lumbar vertebral disc degeneration. This study is a valuable experiment to firstly evaluate osteoporotic vertebral bone and disc degeneration induced by lack of calcium during growth period from a biomechanical and histomorphometrical point of view.

Keywords—Calcium free diet, Disc degeneration, Osteoporosis, in-vivo micro-CT, Finite element analysis, Histology.

I. INTRODUCTION

SUFFICIENT calcium intake during childhood and adolescence is necessary for maintaining peak bone mass [1]. Dietary calcium deficiency may be a dangerous factor for osteoporosis, which may induce the risk of osteoporotic fractures [2]. Osteoporosis, a systemic skeletal disease

D. G. Woo is with Department of Biomedical Engineering, Yonsei University, Wonju, 220-710, Republic of Korea (e-mail: dgwoo@cabe.yonsei.ac.kr).

J. H. Park is with Department of Biomedical Engineering, Yonsei University, Wonju, 220-710, Republic of Korea (e-mail: amia@cabe.yonsei.ac.kr).

C. H. Kim is with Department of Biomedical Engineering, Yonsei University, Wonju, 220-710, Republic of Korea (e-mail: kimchi@cabe.yonsei.ac.kr).

T. W. LEE is with Department of Biomedical Engineering, Yonsei University, Wonju, 220-710, Republic of Korea (e-mail: kimchi@cabe.yonsei.ac.k).

B. Y. Lee is with Department of Anatomy, School of Medicine, Konkuk University, Seoul, Republic of Korea (e-mail: beobyi.lee@kku.ac.kr).

H. S. Kim is with Department of Biomedical Engineering, Yonsei University, Wonju, 220-710, Republic of Korea (corresponding author to provide phone: +81-33-760-2913; fax: +81-33-760-2913; e-mail: hanskim@yonsei.ac.kr).

characterized by a low bone mass, is a major public health problem in the contemporary society because of the high incidence of fragility fractures, especially hip and vertebral fracture [3]-[6]. After the age of 50, bone mineral density (BMD) decreases at a rate as high as 3% per year in postmenopausal women who often have negative calcium balance due to decrease in body calcium absorption, insufficient dietary calcium ingestion, as well as increase in urinary calcium loss associated with estrogen deficiency during menopause [7]. Recently, several researchers investigated the relation between osteoporosis and morphology of vertebral trabecular bone in rats. Hara *et al.* [8] investigated the effect of dietary calcium deficiency in the rat hard palate, mandible and proximal tibia by comparing changes of bone architectures between at 0 week (just before surgery) and at 12 weeks (after surgery). In previous researches, they did not analyze changes in mechanical and histomorphometrical characteristics of osteoporotic vertebral trabecular bone and degenerated disc.

In the present study, we analyzed the generation of osteoporotic vertebral bone induced by lack of calcium during growth period and analyzed its effects for disc degeneration, based on biomechanical and histomorphometrical study.

II. MATERIALS AND METHODS

Animals

20 female Sprague-Dawley rats (6 weeks old, approximate weight 170g) were housed in individually ventilated and cleaned cages (room temperature 23 \pm 2 $^{\circ}$ C, humidity 50 \pm 10%) and it changed day and night the period of 12 hours. All rats were randomly divided into two groups (calcium free diet (CFD) group: 10, normal (NOR) group: 10). All procedures were in accordance with approved National Institute of Health (NIH) Guideline for care and use of laboratory animals under a protocol approved by Yonsei university school of animal care and ethics committee.

3D Morphologies

We acquired 2D cross section images of living rat L1-L6 through high resolution in-vivo micro-computed tomography (μ CT, Skyscan 1076, Skyscan, Belgium) with 35 μ m resolution. 3D structural parameters were calculated from 2D images by CT-An (Skyscan, Belgium). Changes of morphologies were detected and tracked in the trabecular bones of rats (Fig. 1). Fig.

1 shows osteoporosis occurrence via 3D reconstructed models. In the 3D analysis, the tissue volume (TV, mm³) and the trabecular bone volume (BV, mm³) were measured by the direct method, and the trabecular bone volume fraction (BV/TV, %) was calculated. Trabecular thickness (Tb.Th, μm), trabecular separation (Tb.Sp, μm) and trabecular number (Tb.N, mm⁻¹) were directly measured from 3D image data. The plate-rod characteristic of the bone structure was measured by the structure model index (SMI). The SMI value was zero for an ideal plate and three for rod structure.

Mechanical Characteristics

The scanned images were converted to 3D four-node tetrahedral elements images by BIONIX 3.3 (CANTiBio Co., Korea). Four-node tetrahedral elements models with 35μm resolution for FE analysis were generated from 2D images. Simulated compression tests of 3D FE models were performed to investigate the effect of CFD on mechanical characteristics of trabecular bone models in rats (Fig. 2). Displacement boundary conditions were applied to the specimens to simulate the uniaxial compression test. For the elastic characteristic of FE analysis, structural modulus was measured by applying a compressive displacement of 0.5% strain [9]. All FE analyses were performed by using ABAQUS 6.5 (HKS Inc, USA).

Histological analysis

L1-L6 specimens, fixed in formalin, were embedded in paraffin to investigate and analyze the structural changes of intervertebral discs by optical microscope. On the basis of previous study [10], the morphological changes of each motion segment (L4/L5 and L5/L6) was observed, and midsagittal sections of the motion segment were stained with hematoxylin and eosin (H&E) using standard histochemical protocols for a qualitative assessment.

Statistical analysis

All statistical probabilities were performed by using one-way ANOVA test with Tukey'B post hoc multiple comparisons to identify that bone structural parameters and elastic modulus in NOR or CFD groups are constant, increased or decreased over time. The significance level for the statistical analysis was then set at 0.05 (p<0.05).

III. RESULTS

Detailed examination of the matched data sets showed thinning and eventual loss of the metaphyseal trabeculae (Fig. 1). The results of morphological characteristics showed that BV/TV, Tb.Th, Tb.N in CFD group were significantly decreased over time (p<0.05), while those in NOR group were statistically increased over time (p<0.05) in the most lumbar (L1-L6).




Fig. 1 Identification of osteoporosis occurrence via 3D reconstructed models. (a) NOR models, (b) CFD models. There are considerable trabecular bone losses in CFD models.

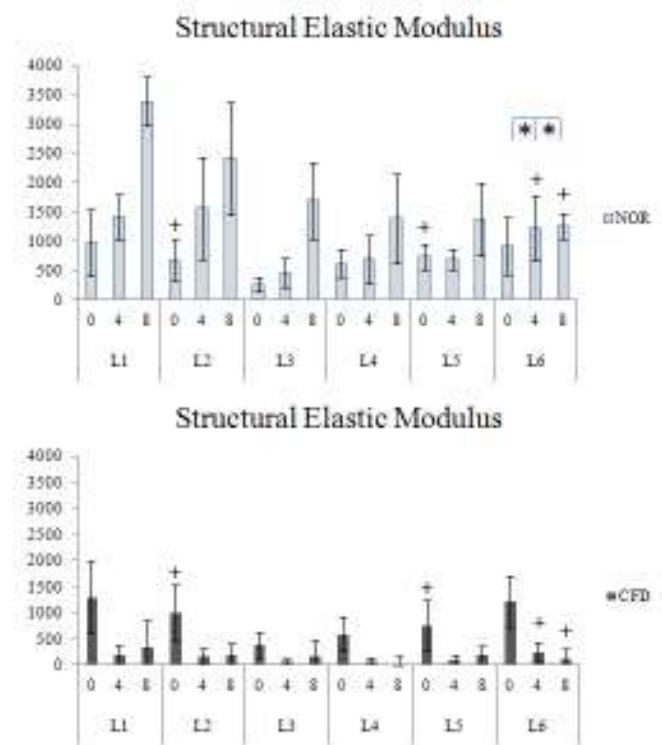


Fig. 2 Changes of mechanical characteristics in NOR and CFD Groups over time (*: non-significant changes in NOR and CFD groups, +: non-significant changes between NOR and CFD on each time (*, +: P>0.05)). All parameters except on *, + were significantly presented.

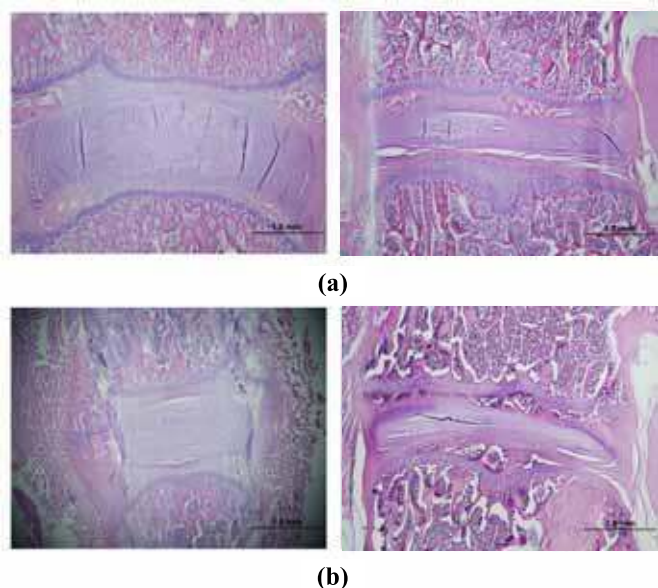


Fig. 3 Verification of typical disc degeneration in histological analysis. (a) Health disc of NOR group (left) and degenerated disc of CFD group (right) on 4 week, (b) Health disc of NOR group (left) and degenerated disc of CFD group (right) on 8 week.

We also investigated the contrary tendency in Tb.Sp and SMI, compared to the above results in each group. In the simulated compression test using FE models, the structural effective modulus of CFD group significantly decreased ($p < 0.05$), whereas that of NOR group was statistically increased, depending on the measuring time ($p < 0.05$) (Fig. 2). The present study observed remarkable histological changes of nucleus pulposus and annulus fibrosus caused by water loss in CFD group, as compared with NOR group.

IV. DISCUSSION

In the present study, morphological and mechanical characteristics of vertebral trabecular bones and intervertebral discs of living rats with CFD were detected and tracked by using high resolution in-vivo micro-CT and micro-FE analysis in order to investigate the effect of CFD and on generation of osteoporosis and disc degeneration.

Our findings indicated that calcium insufficiency was the main factor in the generation of osteoporosis and it induced lumbar vertebral disc degeneration. This study is a valuable experiment to firstly evaluate osteoporotic vertebral bone and disc degeneration induced by lack of calcium during growth period from a biomechanical and histomorphometrical point of view.

REFERENCES

[1] F.R. Greer and N.F. Krebs, "Optimizing bone health and calcium intakes of infants, children, and adolescents" *Pediatrics*, vol. 117, no. 2, pp. 578-585, 2006.
[2] B.L. Langdahl, A.G. Loft, E.F. Eriksen, L. Mosekilde, P. Charles, "Bone mass, bone turnover, body composition, and calcium homeostasis in

former hyperthyroid patients treated by combined medical therapy" *Thyroid*, vol. 6, no. 3, pp. 161-168, 1996.

[3] C. Gennari, "Calcium and vitamin D nutrition and bone disease of the elderly" *Public health nutr.* vol. 4, no. 2B, pp. 547-559, 2001.
[4] M. van der Klift and H. A. P. Pols, "Assessment of fracture risk: Who should be treated for osteoporosis?" *Best Practice & Research Clinical Rheumatology*, vol. 19, no. 6, pp. 937-950, 2005.
[5] C. Cooper, "Osteoporosis: An Increasing Public Health Problem" *Medicographia*, vol. 24, no. 4, pp. 277-284, 2002.
[6] P. D. Delmas, "Treatment of Postmenopausal Osteoporosis" *The Lancet*, vol. 359, no. 9322, pp.2018-2026, 2002.
[7] B. Kaplan, M. Hirsch, "Current approach to fracture prevention in postmenopausal osteoporosis" *Clin Exp Obstet Gynecol*, Vol. 31, no. 4, pp. 251-255, 2004.
[8] T. Hara, T. Sato, M. Oka, S. Mori and H. Shirai, "Effects of ovariectomy and/or dietary calcium deficiency on bone dynamics in the rat hard palate, mandible and proximal tibia" *Arch. Oral. Biol*, Vol. 46, no. 5, pp. 443-451, 2001.
[9] D. G. Woo, Y. Y. Won, H. S. Kim and D. Lim, "A Biomechanical Study of Osteoporotic Vertebral Trabecular Bone: The Use of Micro-CT and High-Resolution Finite Element Analysis" *Journal of Mechanical Science and Technology*, vol. 21, no. 4, pp. 593-601, 2007.
[10] L. Bresnahan, A.T. Ogden, R.N. Natarajan, R.G. Fessler, "A Biomechanical Evaluation of Graded Posterior Element Removal for Treatment of Lumbar Stenosis" *Spine*, Vol. 34, no. 1, pp. 17-23, 2008.