

Segmentation of Lungs from CT Scan Images for Early Diagnosis of Lung Cancer

Nisar Ahmed Memon, Anwar Majid Mirza, and S.A.M. Gilani

Abstract—Segmentation is an important step in medical image analysis and classification for radiological evaluation or computer aided diagnosis. The CAD (Computer Aided Diagnosis) of lung CT generally first segment the area of interest (lung) and then analyze the separately obtained area for nodule detection in order to diagnosis the disease. For normal lung, segmentation can be performed by making use of excellent contrast between air and surrounding tissues. However this approach fails when lung is affected by high density pathology. Dense pathologies are present in approximately a fifth of clinical scans, and for computer analysis such as detection and quantification of abnormal areas it is vital that the entire and perfectly lung part of the image is provided and no part, as present in the original image be eradicated. In this paper we have proposed a lung segmentation technique which accurately segment the lung parenchyma from lung CT Scan images. The algorithm was tested against the 25 datasets of different patients received from Ackron Univeristy, USA and AGA Khan Medical University, Karachi, Pakistan.

Keywords—Computer Aided Diagnosis, Medical Image Processing, Region Growing, Segmentation, Thresholding,

I. INTRODUCTION

COMPUTER aided diagnosis of lung CT image has been a remarkable and revolutionary step, in the early and premature detection of lung abnormalities. The CAD systems include systems for 'automatic detection of abnormality nodules' and '3D reconstruction of lung' systems, which assist the radiologists in their final decisions. Image processing algorithms and techniques are applied on the images to clarify and enhance the image and then to separate the area of interest from the whole image. The separately obtained area is then analyzed for detection of nodules to diagnose the disease [1].

The accuracy and higher decision confidence value of any lung abnormality identification system lies and depends on an efficient lung segmentation technique. It is therefore vital for

Manuscript received on July 4, 2006. This work was supported in part by the Quaid-e-Awam University, Pakistan under faculty development programme.

N.A Memon is graduate student of Faculty of Computer Science and Engineering at GIK Institute, Pakistan (e-mail: memon_nisar@yahoo.com).

A.M. Mirza is with the Ghulam Ishaq Khan Institute of Engineering Sciences and Technology, NWFP, Paksitan (e-mail: mirza@giki.edu.pk).

S.A.M. Gilani is with Ghulam Ishaq Khan Institute of Engineering Sciences and Technology, NWFP, Paksitan (e-mail: asif@giki.edu.pk).

effective performance of the system that the entire and perfectly complete lung part of the image is provided to it and no part, as present in the original image be eradicated.

A. Lung Cancer

The organs and tissues of the body are made up of tiny building blocks called cells. Cells in different parts of the body may look and work differently but most reproduce themselves in the same way. Cells are constantly becoming old and dying, and new cells are produced to replace them. Normally, the division and growth of cells is orderly and controlled but if this process gets out of control for some reason, the cells will continue to divide and develop into a lump which is called a tumour. Tumours can either be benign or malignant [2], as shown in Fig.1. Cancer is the name given to a malignant tumour. A cancerous (malignant) tumour consists of cancer cells which have the ability to spread beyond the original site. If left untreated, they may invade and destroy surrounding tissues. Sometimes cells break away from the original (primary) cancer and spread to other organs in the body by traveling in the bloodstream or lymphatic system. When these cells reach a new area of the body they may go on dividing and form a new tumour, often referred to as a "secondary" or a "metastasis". It is important to realize that cancer is not a single disease with a single type of treatment. There are more than 200 different kinds of cancer, each with its own name and treatment.

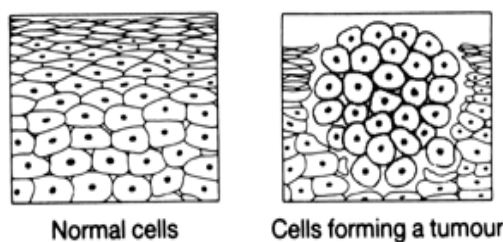


Fig. 1 Normal and Benign cells

Lung Cancer is the malignancy of lungs that is the leading cause of cancer deaths for both men and women globally. About 90 percent of all lung cancer occurs in current or former smokers. The American Cancer Society estimates that 164,000 new cases of lung cancer are diagnosed annually in the United States and an estimated 157,000 people die from the disease each year [3]. According to the Canadian Cancer

Society, 20,600 new cases of lung disease are diagnosed in Canada annually, and the disease causes 17,700 deaths a year. Most cases are diagnosed between the ages of 55 and 65. The number of yearly deaths almost equals the number of new cases. Symptoms do not appear until the disease is quite advanced.

B. Computed Tomography (CT)

Computed Tomography, also known as computed axial tomography, or CAT scan is a medical technology that uses X rays and computers to produce three-dimensional images of the human body. Unlike traditional X rays, which highlight dense body parts, such as bones, CT provides detailed views of the body's soft tissues, including blood vessels, muscle tissue, and organs, such as the lungs. While conventional X rays provide flat two-dimensional images, CT images depict a cross-section of the body. Fig. 2 shows a typical CT scan image [4].

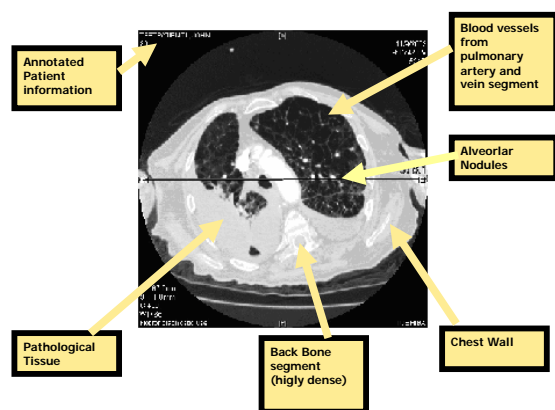


Fig. 2 Typical CT Scan image

A patient undergoing a CT scan rests on a movable table at the center of a donut-shaped scanner, which is about 2.4 m (8 ft) tall. The CT scanner contains an X-ray source, which emits beams of X rays; an X-ray detector, which monitors the number of X rays that strike various parts of its surface; and a computer. The source and detector face each other on the inside of the scanner ring and are mounted so that they rotate around the rim of the scanner. Beams from the X-ray source pass through the patient and are recorded on the other side by the detector. As the source and detector rotate in a 360° circle around the patient, X-ray emissions are recorded from many angles. The resulting data are sent to the computer, which interprets the information and translates it into images that appear as cross-sections on a television monitor. By moving the patient within the scanner, doctors can obtain a series of parallel images, called slices. This series of slices is then analyzed to understand the three-dimensional structure of the body.

C. Medical Image Segmentation

Image segmentation refers to the process of partitioning an image into distinct regions by grouping together neighborhood pixels based on the some predefined similarity criterion. The similarity criterion can be determined using specific properties or features of pixels representing objects in the image. In other words, segmentation is a pixel classification technique that allows the formation of regions of similarities in the image [5].

Segmentation has been remained as an important tool in medical image processing and it has been useful in many applications. The applications include detection of the coronary border in angiograms, multiple sclerosis lesion quantification, surgery simulations, surgical planning, measuring tumor volume and its response to therapy, functional mapping, automated classification of blood cells, studying brain development, detection of micro calcification on mammograms, image registration, atlas matching, heart image extraction from cardiac cine angiograms, detection of tumors etc [6].

In medical imaging, segmentation is important for feature extraction, image measurements, and image display. In some applications it may be useful to classify image pixels into anatomical regions, such as bones, muscles, and blood vessels, while in others into pathological regions, such as cancer, tissue deformities and multiple sclerosis lesions. In some studies the goal is to divide the entire image into sub regions such as the white matter, gray matter, and cerebrospinal fluid spaces of the brain, while in others on specific structure has to be extracted, for example breast cancer from Magnetic Resonance images.

II. RELATED WORK

Samuel et al. [7] has introduced the use of Ball-Algorithm for the segmentation of lungs. At first stage, each CT-Image is gray level thresholded to segment the thorax from background and then the lungs from the thorax. In next step, rolling ball algorithm is applied to the lung segmentation contours to avoid the loss of juxtapleural nodules. The authors have used 17-case database for verifying the results with the help of radiologists. Julian Ker [8] has introduced an other method of segmentation which he has called TRACE method for the segmentation of lungs. Since the size, shape and texture of lungs vary considerably between patients, and among the images of a single patient, which is due to the possible presence of various disease processes, and the change of the anatomy with vertical position. Consequently, the boundary between lung and surrounding tissues can vary from a smooth-edged, sharp-intensity transition to irregularly jagged edges with a less distinct intensity transition. The TRACE algorithm has been developed with the idea of a non-approximating technique for edge detection and representation in mind. Shiyong et al. [9] have presented a fully automatic method for identifying lungs in 3D pulmonary X-Ray CT images. The method is divided into three main steps: 1) lung region is extracted from CT-Scan

image by gray-level thresholding, 2) left and right lungs are separated by identifying the anterior and posterior junctions by dynamic programming and 3) sequence of morphological operations is used to smooth the irregular boundary along the mediastinum in order to obtain results consistent with those obtained by manual analysis, in which only most central pulmonary arteries are excluded from the lung region. Riccardo Boscolo et al. [10] has used novel segmentation technique that combines a knowledge based segmentation system with a sophisticated active contour model. This approach exploits the guidance of a higher-level process to robustly perform the segmentation of various anatomic structures. The user need to provide initial contour placement, and the high-level process carries out the required parameter optimization automatically. Ayman El-Baz et al. [11] have developed a fully automatic Computer-Assisted Diagnosis (CAD) system for lung cancer screening using chest spiral CT scans. This paper presents the first phase of an image analysis system for 3-D reconstruction of the lungs and trachea, detection of the lung abnormalities, identification or classification of these abnormalities with respect to specific diagnosis, and distributed visualization of the results over computer networks. Binsheng et al. [12] has used the method of selecting the threshold by analyzing the histogram. The threshold is then used to initially separate the lung parenchyma from the other anatomical structures on the CT images. As the apparent density of voxels and bronchial walls in the lungs differ, structures with higher densities including some higher density nodules could be grouped into soft tissues and bones, leading to an incomplete extraction of lung mask. To obtain complete hollow free lung mask, morphological closing is applied. Spherical shape of the structural element is chosen for morphological operator and the filter size is approximately determined. With the help of 3D mask, the lungs can be readily extracted from the original chest CT images. Ayman El-Baz et al. [13] have used the optimal gray-level thresholding for the extraction of thorax area. Once the threshold has been selected and applied, region growing and connectivity analysis are used to extract the exact cavity region with accuracy. This scheme gives the promising results for all CT-Sections which have unique intensities of lung parenchyma.

The [9],[11] and [13] have used iterative gray level thresholding for the extraction thorax and lungs from the CT Scan images. For these mentioned techniques and few more like region growing [14] and active contour method [14], it is necessary for their accurate and precise performance that there should be a distinct outer black region, which should enclose the lung parenchyma and the adjoining features. However, it may happen that the lung tissue and cavities may not be enclosed in a completely black outline, and thus these methodologies may only work partially.

III. PROPOSED METHOD

The goal of the lung segmentation required for the computer aided diagnosis from CT scan images is to essentially separate the voxels corresponding to the lung cavity in the axial CT scan slices from the surrounding lung anatomy. We have proposed a scheme that first performs an optimal thresholding which selects the threshold based on the object and background pixel means. Once the threshold has been selected and applied, region growing and connectivity analysis are then used to extract the exact cavity region with accuracy.

A. Optimal Thresholding

We assume for each image that the image can be separated into two types of voxels, as characterized by the density differences between the two anatomical structures (usually these density-based characterization can be directly obtained from CT scan equipment): 1) Voxels within the very dense body and chest wall structures (the *body* voxels) and 2) Low-density voxels in the lungs or in the air surrounding the body of the subject (the *nonbody* voxels).

Thus, the essential aim of optimal thresholding is to separate the body voxels (soft lung tissue) from the lung cavities (non-body voxels). The lung cavities are usually low-density structures. Since low density structures are usually represented as relatively dark regions on CT scans, contrast-based segmentation is possible.

(a) *Starting Threshold – Mean of the Axial Slice Image:* A reasonably accurate threshold for the image as a start is the mean of all the pixel values in the image. The mean value of the pixels is selected as the beginning value for the computation of the threshold iteratively in the next step.

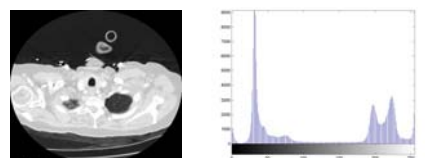
(b) *Iterative Thresholding:* The segmentation threshold selection is best described as an iterative procedure. Let T^i be the segmentation threshold after the i^{th} step. To choose a new segmentation threshold, we apply T^i to the image to separate the voxels into body and nonbody voxels. Let μ_0 and μ_n be the mean gray-level of the body voxels and nonbody voxels after segmentation with threshold T^i . Then the new threshold for step $i+1$ is

$$T^{i+1} = \frac{1}{2}(\mu_b + \mu_n) \quad (1)$$

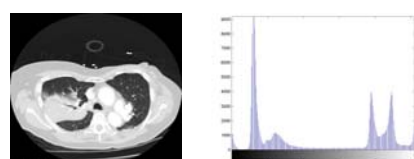
This iterative approach continues until the threshold converges. What this means is that two consecutive iterations yield threshold values with minimum difference i.e. difference which can be ignored for all practical purposes.

The threshold computed for one image in the CT scan case cannot be used for all the images since the grey level variations in each image for a specific case are quite large and must be catered to by the segmentation algorithm. This variation in grey levels is highlighted by the histograms shown in Fig. 3(a),3(b) and 3(c). Also the number of voxels which fall in a particular grey-level bin differs in each slide. This means that the number of object and background voxels differs considerably in each slide. Hence, the iterative

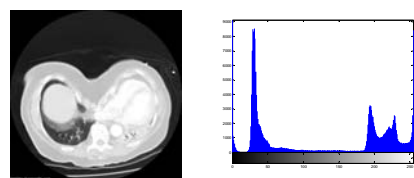
threshold for each image is different which yields optimum results. Thus, we are obliged to apply the above thresholding method to all the images of a particular case.



(a) Histogram of an axial slice of the start of lung



(b) Histogram of an axial slice of the middle of the lung



(c) Histogram of an axial slice of the end of the lung

Fig. 3 Images and their corresponding histograms

B. Connectivity Analysis

After applying the optimal threshold, the nonbody voxels will correspond to the air surrounding the body, the lungs, and other low-density regions within the image volume (i.e., gas in the bowel). The next step is the connectivity analysis of the thresholded image and the segmentation of the lung cavities from the thresholded image via region growing.

(a) *Selection of Seed Pixel:* Essentially, a seed pixel must be selected from which the region growing may commence. Since the aim of this part of the segmentation process is the removal of the dark areas adjoining the lung parenchyma, a seed pixel must be selected from the dark region. The approach selected here finds the minimum pixel from the image on the boundary. This is a dark pixel (grey level 0) in most cases.

C. Region Growing

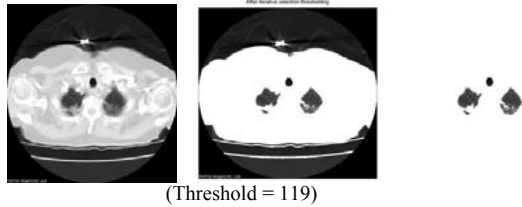
Once the dark pixel coordinates are selected (background air), region growing commences in the form of marking all the pixels which lie in the 8-connected neighbourhood of the seed pixel. The process is repeated for each pixel until all the black pixels are marked in the image which adjoin the areas of the lung parenchyma. This essentially deletes the dark regions that are connected to the border of the image. Since

the goal of the segmentation process is to segment the lung cavities, we have full liberty in assigning the same grey-level intensity to the adjoining black pixels as the lung parenchyma. To distinguish between the white regions already present in the lung parenchyma and the white regions generated because of the background air volume, the white regions of the lung parenchyma are tagged before region growing commences. This is because if the region-growing algorithm was only moderated according to gray-levels, the region growing algorithm would extend on the complete image. The enclosing property of the white parenchyma is retained by tagging the white parenchyma before region growing commences from the border regions towards the inside. After the region-growing based 8-connectivity analysis of the image, the original gray-scale image has been segmented into the lungs and trachea. The results are shown in Fig. 4(a), 4(b) and 4(c).

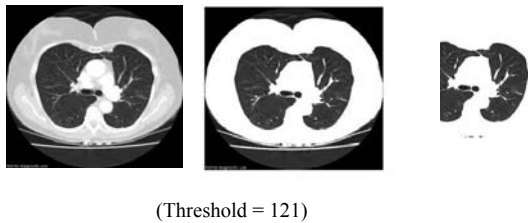
D. Pre-Processing of Image before Thresholding

The approach mentioned above selects the minimum pixel from the sides of the image as the seed pixel and starts region growing and whitening from that spot. In most of the cases available, there is a distinct outer black region which completely encloses the lung parenchyma and the adjoining features. It may however happen that the lung tissue and the cavities and the chest wall may not be enclosed in a completely black outline and thus, region growing may only work partially. The example of such an image is shown in Fig. 5(a) in which the chest wall partially overlaps with the boundaries of the image. The Fig. 5(b) shows the thresholded image of such a specific case. If region growing on the image shown in Fig. 5(b) is conducted without any pre-processing, it would stop towards the left most region while the bottom-left, bottom-right and top-right dark areas of the image will still remain black. Fig. 5(c) shows such result. In such a scenario, some pre-processing is required. The 8-connectivity analysis to completely flood the region with the specific grey level requires that at least a single-pixel path be available which should connect the various dark regions. This single pixel path is usually available in the images but in specific cases (as described above) the path might not be available since the border of the lung parenchyma overlaps with the border of the image. To avoid this scenario of partial deletion of the background, a one-pixel wide border of the image is turned to zero grey-level intensity (black) so that the connecting path may be provided, as shown in Fig. 5(d). This does not interfere with our region of interest i.e. the lung cavities while it also provides a single-pixel wide path connecting all the dark regions in the image. This pre-processing can also be used to avoid the determination of the minimum seed pixel for any small areas that may be dark and overlap with the borders. Partially dark spots on the image boundary each shall need a different seed-pixel to start region-growing. This approach ensures that a minimum pixel (grey-level = 0) shall completely delete all the dark areas of the image.

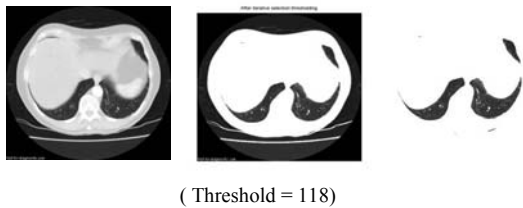
The approach can also be used in a different manner which shall also ensure that not even the boundary pixels (usually insignificant) are lost. Instead of marking the boundary pixels as black, a boundary of black pixels may be added to the image and the border may be selected as the seed pixel. This shall yield the same result as shown in Fig. 5(e).



(a) Original, thresholded and segmented image of the beginning of the lung



(b) Original, thresholded and segmented image of the middle of the lung



(c) Original, thresholded and segmented image of the end of the lung

Fig. 4 Original and segmented images with thresholds on which thresholding was performed

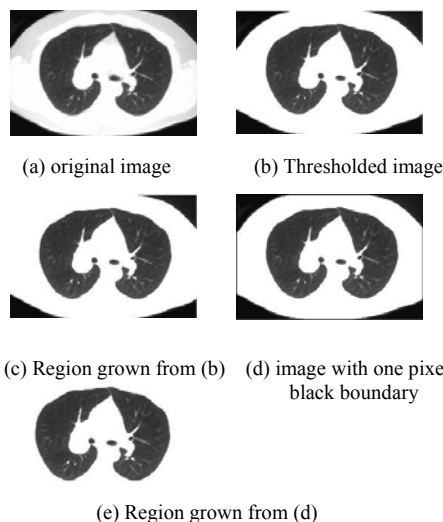


Fig. 5 Different region grown with and without pixel boundary

IV. DATA CHARACTERISTICS

The following are the major features of the segmented data set:

1. 512 x 512 pixels of each image
2. 8-bit grey scale images (255 grey levels)
3. Slice Thicknesses of varying data
4. The lung cavities also have pathology in certain cases.

V. DISCUSSION

The segmentation algorithm starts off with the basic pre-processing of the image by either appending a one-pixel wide black boundary or setting the outermost boundary layer of the image to zero intensity. This is necessary to ensure that if the seed pixel selected once shall suffice to delete all the background regions by region-growing when the process starts. Thus, we ensure that for each region of background, we will not have to select a seed-pixel for region growth. The optimum threshold for a particular data set in CT depends on the following basic factors – tissue volume, air volume, density units of tissue, image acquisition methodology and properties of contrast in the image owing to the lung parenchyma (lung tissue). Since these factors may vary with each case and for each 512 x 512 image within a case, the optimum threshold is selected for each and every image in each and every case that is encountered. Generally there is little variation in the threshold across repeated scans of the same subject while miniature differences exist when conducting the study across subjects. Optimum thresholding performs better when lung volumetric differences are unavoidable.

The thresholding problem essentially is an oscillation of the threshold before convergence to an optimum value. This value is, after several iterations, the mean of the background pixels and the object pixels (background air and the lung). It must be emphasized upon here that the threshold selection is successful because of the stark difference between the lung tissue density and the lung cavity volume. This difference in density ensures that the image can easily be characterized into object and background pixels and thus, computation of the mean of each feature's intensity (background and object) is facilitated.

The 8-connected region growing portion of the algorithm is the part which has a high time complexity because each and every pixel is checked for its neighbourhood to determine whether it is tagged or not. Thus, for each pixel which has an adjoining white pixel, the iteration compares the entire neighbourhood and depending on whether it is in the central region of elimination, or, in line with the boundary of the tagged image (explained previously) sets the intensity level of the pixels accordingly. Note that the tagged portion of the image is not set to an intensity level and thus, the lung cavity and the associated internal structures are retained.

The smoothing of the lung cavities was not conducted deliberately as it is not appropriate for the application for which the segmentation process was being conducted.

Accuracy of the edge of the lung may be lost by smoothing and thus, the exact contour cannot be retained.

REFERENCES

- [1] M. A. Khawaja, Muhammed Zaheer Aziz, Nadeem Iqbal, "Effectual Lung Segmentation for CAD Systems Using CT Scan Images", Proceedings of IEEE, INMIC Conference, FAST Lahore, 2004.
- [2] Robin N. Strickland, "Image Processing Techniques for Tumor Detection", Marcel Dekker Inc. New York, 2002.
- [3] R Wicmker PhD, P. Rogalla MD, T Blaffert PhD, "Aspects of Computer-aided detection (CAD) and volumetry of pulmonary nodules using multislice CT", The British Journal of Radiology (BJR), vol. 78, pp. 46-56, 2005.
- [4] Malin Dollinger, "Every one's Guide to Cancer therapy; How Cancer is Diagnosed, Treated and Manged", 4th Edition, Andrews McMeel Publishing Kansas, USA, 2002.
- [5] Atam P. Dhawan, "Medical Image Analysis", IEEE press series in Biomedical Engineering, John Wiley & Sons. Inc. Publications, 2003.
- [6] Jadwiga Kogowska, "Overview and Fundamental of Medical Image Segmentation", Hand Book of Medical Imaging, Academic Press, San Diego, pp. 69-85, 2000.
- [7] Samuel G. Armato III, Maryellen L. Giger and Catherine J. Moran, "Computerized Detection of Pulmonary Nodules on CT Scans", RadioGraphics, vol. 19, pp. 1303-1311, 1999.
- [8] Julian Kerr, "The TRACE method for Segmentation of Lungs from Chest CT images by Deterministic Edge Linking", University of New South Wales, Department of Artificial Intelligence, Australia, May 2000.
- [9] Shiyong Hu, Eric A. Huffman, and Joseph M. Reinhardt, "Automatic Lung Segmentation for Accurate Quantitation of Volumetric X-Ray CT images", IEEE Transactions on Medical Imaging, vol. 20, No. 6, June 2001.
- [10] Riccardo Boscolo, Mathew S. Brown, Michael F. McNitt-Gray, "Medical Image Segmentation with Knowledge-guided Robust Active Contours", Radiographics, vol. 22, pp. 437-448, 2002.
- [11] Ayman El-Baz, Aly A. Farag, Ph.D., Robert Falk, M.D. and Renato La Roca, "Detection, Visualization, and Identification of Lung Abnormalities in Chest Spiral CT Scans: Phase 1", International Conference on Biomedical Engineering, Cairo, Egypt, 12-1-2002.
- [12] Binsheng Zhao, Gordon Gamsu, Michelle S. Ginsberg, "Automatic detection of small lung nodules on CT utilizing a local density maximum algorithm", Journal of Applied Clinical Medical Physics, vol. 4, No. 3, summer 2003.
- [13] Ayman El-Baz, Aly A. Farag, Ph.D., Robert Falk, M.D. and Renato La Roca, "A unified approach for detection, visualization, and identification of lung abnormalities in chest spiral CT scans", proc. Computer Assisted Radiology and Surgery, London, 2003.
- [14] Shu-Yen Wan, William E. Higgins, "Symmetric Region Growing", IEEE Transactions on Image Processing, Vol. 12, No. 8 August 2003.

Nisar Ahmed Memon did his BE(CS) from Mehran University of Engineering and Technology. At present he is Ph.D Scholar at Faculty of Computer Science and Engineering, Ghulam Ishaq Khan Institute of Engineering Sciences and Technology, Pakistan. He is also a faculty member of Quaid-e-Awam University of Engineering Sciences and Technology, Paksitan. His research interest include, Medical Image Processing, Digital Watermarking of Medical Images, Data Authentication and security.

Dr. Anwar Majid Mirza is keenly interested in the areas of design and analysis of Neuro-Fuzzy Systems, Image Processing, Artificial Intelligence and Computational Physics. He is currently supervising four HEC sponsored PhD scholars working in the areas of Evolutionary Programming, Pattern Recognition, Image Restoration, Medical Imaging and Wavelet- & Finite Element- solution of partial differential equations. He has also been supervising both MS and undergraduate students at the GIK institute in the areas of Evolutionary Robotics, Computer Vision and Modeling & Simulation. His PhD research work on modeling and simulation has been

cited at numerous places including the book entitled "Finite Element Methods for Particle Transport" published by John Wiley & Sons in 1997.

Dr. Asif Mehmood Gilani is specialized in the field of Image Processing especially in the Data Security Issues. His research has been focused on the study of Digital Image Watermarking for Copyright Protection. In addition, he is researching in other security applications like Data Authentication and Image Steganography. Also have interest in the areas of Computer Simulation of physical systems. He has been involved in teaching and research at undergraduate as well as postgraduate levels and has supervised students both within and outside Pakistan over a period of ten years. Dr. Gilani has been awarded with the distinction in M.Sc., and Ph.D., Scholarship from the Greek State. He has published a number of research papers Internationally and is at the list of HEC and PCST approved Ph.D. Supervisors.