

# A Comparison on Healing Effects of an Ayurvedic Preparation and Silver Sulfadiazine on Burn Wounds in Albino Rats

S. S. Pathak, M. A. Borkar, and S. S. Patel

**Abstract—Objective:** To compare Healing Effects of an Ayurvedic Preparation and Silver Sulfadiazine on burn wounds in Albino Rats.

**Methods:** Albino rats—30 male / female rats weighing between 150-200g were used in the study. They were individually housed and maintained on normal diet and water *ad libitum*. Partial thickness burn wounds were inflicted, on overnight-starved animals under pentobarbitone (30mg/kg, i.p.) anesthesia, by pouring hot molten wax at 80°C into a plastic cylinder of 300mm<sup>2</sup> circular openings placed on the shaven back of the animal. Apart from the drugs under investigation no local/ systemic chemotherapeutic cover will be provided to animals. All the animals were assessed for the percentage of wound contraction, signs of infection, scab formation and histopathological examination.

**Results:** Percentage of wound healing was significantly better in the test ointment group compared to the standard. Signs of infection were observed in more animals in the test ointment group compared to the standard. Scab formation also took place earlier in the test ointment group compared to standard. Epithelial regeneration and healing profile was better in the test ointment compared to the standard. Moreover the test ointment group did not show any raised margins in the wound or blackish discoloration as was observed in silver sulfadiazine group.

**Conclusion:** The burn wound healing effect of the ayurvedic ointment under study is better in comparison to standard therapy of silver sulfadiazine. The problem of infection encountered with the test ointment can be overcome by changing the concentrations and proportions of the ingredients in the test ointment which constitutes the further plan of the study.

**Keywords—**Ayurvedic test ointment, burn wounds, Silver sulfadiazine.

## I. INTRODUCTION

WOUND ulcer is the break in the continuity of epithelium. Wound Ulcer is either caused due to infection, trauma or burns. Out of these wounds caused due to trauma and burns are the commonest. Some of the major complications of the wounds are the development of infections and post wound contractures. [1] The present study is an effort to test the effectiveness of an Ayurvedic preparation in promoting the healing of the burn wounds, in preventing the complications and test its effectiveness by comparing it with

the standard preparation silver sulfadiazine.

The ointment Silver sulfadiazine which is extensively used for the treatment burns comes with the disadvantages of delayed separation of scar, delayed reepithelisation, and staining of the skin [2], [3].

Hence a drug which will not only prevent the infection but also will prevent the delay of the scar separation, delay of reepithelisation, and staining of skin is required.

The Ayurvedic preparation was prepared using Neem Leaves (*Azadirachta indica* A. Juss), Sal Resin (*Shorea robusta* Gaerth. F.) and Linseed Oil (*Linum usitatissimum* L.) and is named in Sanskrit as Atasthadi Lep.

### A. Thermal Burns [4]-[7]

1<sup>st</sup> and 2<sup>nd</sup> degree burns are known collectively as partial thickness burns. 2<sup>nd</sup> degree burns is the deeper injury than 1<sup>st</sup> degree burn. It involves all the epidermis and much of the corium. The deep dermal burn is of significant clinical importance.

Most 2<sup>nd</sup> degree burns are characterized by blisters. They are usually accompanied by considerable subcutaneous oedema. The rate of healing is dependent upon the depth of skin destruction on whether or not presence of infection. In superficial partial thickness burns, healing usually occurs uneventfully in a period of 10 to 14 days unless infection supervenes.

Deep dermal burns are injuries that extend down deep in the corium lining of the sweat glands and their follicles.

If the wound is properly protected it will be covered with a thin layer of epithelium in 25 to 35 days. There may be thick scarring.

TABLE I  
CHARACTERISTICS OF VARIOUS DEPTH OF BURN INJURY

Depth of burn	Cause	Surface	Colour	Pain Sensation
1st degree	Sun or minor flash	Dry no blisters	Erythematous	Painful
2nd degree	Flash or hot liquids	Blisters, moist	Mottled red	Painful
3rd degree	Flame	Dry	Partly white or charred	Little pain, anesthetic

It is now common knowledge that the deep burns heal with hypertrophic scars. The healing dermis microscopically presents with ubiquitous myofibroblasts this fibroblast like cells attach to the adjacent collagen fibers. It has been postulated that the microfibroblasts are responsible for the

Pathak S. S. is Associate Professor with the Dept. of Pharmacology JNMC, Sawangi, Wardha (e-mail: swanandspathak@yahoo.com).

Borkar M.A. is Assistant Professor with the Dept. of Pharmacology JNMC, Sawangi, Wardha.

Patel S. S. is Professor with the Dept. of Pharmacology JNMC, Sawangi, Wardha.

burn scar contracture and collagen disorientation characteristic of hypertrophic burn scar [8].

#### B. Standard Used for the Comparison Silver Sulfadiazine Cream (1%)

##### 1. Category

Burns; Pregnancy Category B; WHO Formulary3

##### 2. Drug Class

Anti-infectives, topical; Dermatologics

##### 3. Description [9]

1% cream is a soft, white, water-miscible cream containing the antimicrobial agent silver sulfadiazine in micronized form. Each gram of silver sulfadiazine cream 1% contains 10 mg of micronized silver sulfadiazine. The cream vehicle consists of white petrolatum, stearyl alcohol, isopropyl myristate, sorbitan monooleate, polyoxyl 40 stearate, propylene glycol, and water, with methylparaben 0.3% as a preservative. Silver sulfadiazine cream 1% spreads easily and can be washed off readily with water off readily with water.

##### 4. Clinical Pharmacology [10], [11]

Gives broad spectrum prophylaxis against bacterial colonization and is particularly effective against *Pseudomonas aeruginosa* and also methicillin resistant *Staphylococcus aureus*. The silver sulfadiazine cream is the best treatment of choice for the burn wounds.

##### 5. Indications

Silver sulfadiazine cream 1% is a topical antimicrobial drug indicated as an adjunct for the prevention and treatment of wound sepsis in patients with second- and third-degree burns.

##### 6. Limitations

- Delayed separation of scar
- Delayed reepithelisation,
- Development of post burn contractures
- Staining of the skin.
- Silver sulfadiazine cream 1% is contraindicated in patients who are hypersensitive to sulfadiazine or any of the other ingredients in the preparation.
- Because sulfonamide therapy is known to increase the possibility of kernicterus, silver sulfadiazine cream 1% should not be used on pregnant women approaching or at term, on premature infants, or on newborn infants during the first 2 months of life.
- The use of silver sulfadiazine cream 1% in some cases of glucose-6-phosphate dehydrogenase-deficient individuals may be hazardous, as hemolysis may occur.
- Other infrequently occurring events include skin necrosis, erythema multiforme, burning sensation, rashes, and interstitial nephritis.
- However, reduction in bacterial colonization has caused delayed separation, in some cases necessitating escharotomy in order to prevent contracture.

#### C. Ingredients of the Ayurvedic Preparation

The idea of the preparation was taken from the notes of

Ayurvedacharya Late Shri. N. R. Shukla which was an unpublished data.

##### 1. *Azadirachta indica* A. Juss [12],[13]

Vernacular name: Sanskrit – Nimbah Eng: Neem Tree

Description: A medium to large sized tree, 15-20m in height with a clear bole of 7m having grayish dark tubercled bark, leaves compound, imparipinnate, leaflets subopposite, serrate, very oblique at base, flowers cream or yellowish white.

Habitat: Throughout India.

Parts used in the preparation: Leaves, flowers or fruits.

Chemical Constituents: Leaves contain Nimbin, nimbinene, 6- decacetylnimbinene, nimbandiol, nimbolide and quercetin. Presence of  $\beta$ -sitosterol, n-hexacosanol and nonacosane is also reported. Analysis of mature leaves gives moisture, protein, fat, fibres, carbohydrates and minerals, calcium, phosphorus, iron, thiamine, niacin, vitamin, carotene. The amino acids are glutamic acid, tyrosine, aspartic acid, alanine proline and glutamine.

Associated uses: Leaves are antiseptic, astringent, and insecticidal.

They are important in the vital conditions of pitta, burning sensation, leprosy, skin diseases and ulcers.

##### 2. *Shorea robusta* Gaerthn. F [14]

Vernacular name: Eng: Sal Hin: Sal

Description: Large deciduous tree 18-30m in ht. With smooth or longitudinally fissured reddish brown or gray bark, leaves simple, ovate, oblong, acuminate, tough, coriaceous, base cordate or rounded, lateral nerves 12-15 pairs. Flowers: yellowish.

Habitat: North east and central India.

Chemical constituents: 2-(2-iminoacetic acid) – 3- (2H)-benzo- furanone glucoside of 4 hydroxy choline, leuconathocyanidin, hopcaphenol, triterpenoids and a terpene alcohol, furfural, monomethylene and dimethyl ether of homocatechol alkyl benzene derivatives, pentosans, linan, tannin, amino acids and fatty acids.

Parts used in the preparation: Resin

Associated uses: Bark is astringent, acrid, cooling.

Useful in vitiated conditions of kapha and pitta, ulcers, wounds, bacterial infections, leprosy.

Resin is antibacterial, astringent, cooling. It is useful in wound ulcers, burns, neuralgia.

##### 3. *Linum usitatissimum* L. [15]

Vernacular name: Eng – Linseed, Hindi – Alsi

Description: Annual herb 60-120cm ht., Stems solitary, branched, branches ascending towards the apex; leaves up to 3.8cm long, flowers small, blue, bluish violet or white in terminal panicles, seeds compressed.

Habitat: cultivated throughout India

Parts used in the preparation: oil.

Chemical constituents: oil contains moisture, protein, fats, mineral matters as calcium, phosphorus, carotene, thiamine, riboflavin, niacin, pantothenic acid choline, and Vit. E.

Uses: Oil is used for external application it is a common base for liniments. Crushed linseed is applied in the form of

poultice for the relief of local inflammations, ulcers, boils and carbuncles.

## II. MATERIALS AND METHODS

### A. Permission

Permission was obtained from the Animal Ethical Committee of JNMC Sawangi.

### B. Animals Required

Albino rats– 30 male / female rats weighing between 150-200g were used in the study. They were individually housed and maintained on normal diet and water *ad libitum*.

### C. Drugs

Ayurvedic ointment was prepared in the pharmacy laboratory of the Dept. of Pharmacology JNMC under sterile conditions. 20gm of neem leaves were boiled in the linseed oil 500 ml till the color of the oil becomes greenish. It was then allowed to cool at the room temperature. It was then triturated with powdered ral 100gm. The contents were washed 100 times to obtain pure form of Ayurvedic ointment. Silver Sulfadiazine was obtained from the college purchase

### D. Burn Wound Model [16]-[18]

Partial thickness burn wounds were inflicted, on overnight-starved animals under Pentobarbitone (30mg/kg, i.p.) anesthesia, by pouring hot molten wax at 80°C into a plastic cylinder of 300mm<sup>2</sup> circular openings placed on the shaven back of the animal. Apart from the drugs under investigation no local/ systemic chemotherapeutic cover was provided to animals.

### E. Experimental Protocol

Animals bearing the partial thickness burn wounds were distributed into three groups each containing 10 animals as follows

TABLE II  
GROUPING OF ANIMALS

Group	Number of Animals
<b>Control</b> not receiving any treatment	10
<b>Test</b> treated with test ointment	10
<b>Standard</b> treated with Silver Sulfadiazine	10

Test and standard group received daily local application of Test ointment and Silver Sulfadiazine.

The study did not involve the sacrificing of the animals. The animals in the study could be rehabilitated and reused.

### F. Assessment of Burn Healing [19]-[21]

Animals were inspected daily and the healing was assessed based on physical parameters namely, wound contraction and epithelization as well as histological.

### G. Wound Contraction

Wound Contraction was studied by tracing the raw wound area on a transparent polythene paper on day 7, 14 and 21 post wounding days. Later the area assessed using a graph paper. The wound contraction was measured as the percentage

decrease original wound size 300 mm<sup>2</sup> for each animal of group.

### H. Wound Infection

Wound swabs were taken for the culture and sensitivity reporting on the eighth wounding day to determine the presence of any infection in the wound.

### I. Reepithelization

Falling of eschar leaving no raw wound area was considered as end point of complete reepithelization and the days required for this will be taken as period of epithelization.

### J. Histopathology

Samples were collected by excision biopsy on 14th day. Samples were fixed in 10% neutral buffered formalin. Histological evaluation was performed on haematoxylin and eosin stained thin paraffin sections of wound bed material.

### K. Statistical Analysis

Results were reported as mean  $\pm$  SEM. The data was analyzed by unpaired Student's 't' test and one way ANOVA

## III. RESULTS

Results were expressed in the form of percentage of wound healing by taking the tracings of the wound on the graph paper. Observations were recorded and mean was calculated in each group.

Percentage of wound contraction as shown in the Table I and Fig. 1 has the following data – in saline control the percentage of wound contraction was  $41.2 \pm 0.2, 53.7 \pm 1.2, 60.4 \pm 1.30$  on 7<sup>th</sup> 14<sup>th</sup> and 21<sup>st</sup> day respectively compared to silver sulfadiazine  $55.4 \pm 1.3, 62.8 \pm 0.9, 70.5 \pm 1.1$  and the test preparation  $62.6 \pm 1.17, 70.5 \pm 1.9$  and  $85.7 \pm 0.5$

TABLE III  
PERCENTAGE WOUND CONTRACTION

Wound model Parameters studied	Burn Wound Percentage of wound contraction ( Mean $\pm$ S.E.) by days		
	7 <sup>th</sup> day	14 <sup>th</sup> day	21 <sup>st</sup>
Control	$41.2 \pm 0.2$	$53.7 \pm 1.2$	$60.4 \pm 1.30$
Silver sulfadiazine- standard	$55.4 \pm 1.3$	$62.8 \pm 0.9^{**}$	$70.5 \pm 1.1^{**}$
Test ointment	$62.6 \pm 1.17$	$70.5 \pm 1.9^{***}$	$85.7 \pm 0.5^{***}$

\*\* Parameter values (p < 0.001) comparison between silver sulfadiazine and control

\*\*\* Parameter values (p < 0.001) comparison between test ointment and silver sulfadiazine

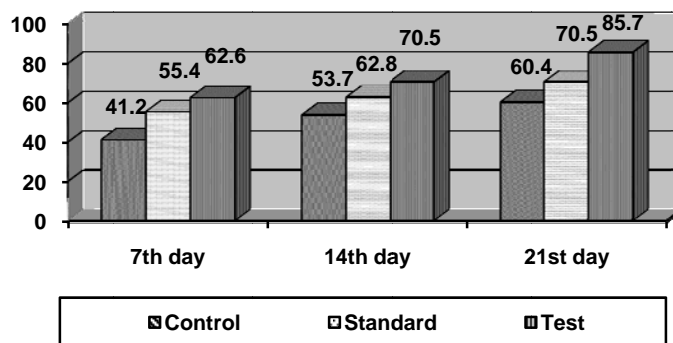


Fig. 1 Representation of the percentage of wound contraction

The signs of infection were observed in 4 animals in saline control, 2 animals in silver sulfadiazine group and 3 animals in the test ointment group.

The scab formation took place on an average on 31<sup>st</sup> day in saline control 26<sup>th</sup> day in silver sulfadiazine and 23<sup>rd</sup> day in the test ointment group.

As shown in the Table II after histopathological examination the epithelial regeneration was quantified as mild (+), moderate (++) and prominent (+++). In the test ointment group 7 animals showed prominent epithelial regeneration compared to 3 in silver sulfadiazine group and nil in the control group.

TABLE IV  
EPITHELIAL REGENERATION GRADING ON HISTOPATHOLOGICAL EXAMINATION

Grading of epithelial regeneration	Mild (+)	Moderate (++)	Prominent (+++)
	Number of animals		
Control	8	2	0
Silver sulfadiazine-standard	3	4	3
Test ointment	1	2	7

Histopathological examination also showed that the ulcer healing process was incomplete in all the animals in control group while 10% animals showed healing of ulcers in silver sulfadiazine group while 20% animals in the test ointment group showed complete healing of the ulcers.

Saline control animals showed raised borders in the healed wounds while silver sulfadiazine group showed normal borders with blackish discoloration. The test group neither showed raised margins nor the blackish borders in the healed burn wounds.

#### IV. DISCUSSION

Percentage of wound healing is significantly better in the test ointment group ( $85.7 \pm 0.5$ ) compared to the standard ( $70.5 \pm 1.1$ ).

Signs of infection observed are more or less equal in the test ointment group compared to the standard.

Scab formation also took place earlier in the test ointment

group (23<sup>rd</sup> day) compared to standard. (26<sup>th</sup> day) Epithelial regeneration and healing profile was better in the test ointment compared to the standard.

Moreover the test ointment group did not show any raised margins in the wound or blackish discoloration as was observed in silver sulfadiazine group.

#### V. CONCLUSION

The burn wound healing effect of the Ayurvedic ointment under study is better in comparison with the standard therapy of silver sulfadiazine. The problem of infection encountered with the test ointment can be overcome by changing the concentrations and proportions of the ingredients in the test ointment which constitutes the further plan of the study in animals. This further evaluation is necessary before starting the clinical trial of the Ayurvedic ointment.

#### REFERENCES

- [1] Curtis P. A., John A. M. In: The Treatment of Burns. Curtis PA, John AM, 2nd ed; Philadelphia, WB Saunders Company;1969 :341.
- [2] Koller J. Topical treatment of partial thickness burns by silver sulfadiazine plus hyaluronic acid compared to silver sulfadiazine alone: a double-blind, clinical study. *Drugs Exp Clin Res.*2004;30 (5-6):183-90.
- [3] Silver Sulfadiazine (Topical), USP DI Drug Information for the Medical Care Professionals, 2000.
- [4] Curtis PA, John AM. The Treatment of Burns.,2nd ed;Philadelphia, WB Saunders Company;1969:142-144
- [5] Robert HD. Burn and Other Thermal Injuries. In: Current Surgical Diagnosis and Treatment. Lawrence WW, Gerard MD, 11th ed; Large Medical Books/McGraw Hill;2003:267
- [6] Mike T. Burns. In: Baily and Love's Short Practice of Surgery. Russel RC, Normans, Williams, Christopher JK, 24th ed, Arnold London; 2004:270.
- [7] Mclachie GR, Leaper DJ. Oxford Handbook of Clinical Surgery. 2nd ed; Oxford University Press, Oxford;2002:497.
- [8] Mathangi K, Plastic Surgery. In: Textbook of Surgery, Ahmad A., Rabindra B. Tata McGraw Hill; New Delhi,2003:1252.
- [9] Jarret F, Ellerbe S, Demling R. Acute leukopenia during topical burn therapy with silver sulfadiazine. *Amer J Surg.*1978; 135:818-819.
- [10] Kiker RG, Carvajal HF, Micak RP, Larson DL. A controlled study of the effects of silver sulfadiazine on white blood cell counts in burned children. *J Trauma* 1977;17:835-836.
- [11] Mike T. Burns. In: Baily and Love's Short Practice of Surgery. Russel RC, Normans, Williams, Christopher JK, 24th ed, Arnold London; 2004:273.
- [12] Prajapati, Purohit, Sharma, Kumar. A Handbook of Medicinal Plants: A Complete Source Book; 1st ed; Agrobios (India), Jodhpur, 2003:79.

- [13] Warriar PK, Nambiar VP, Ramankutty C. Indian Medicinal Plants Vol: 1; 1st ed; Orient Longman, Hyderabad, 1994:227.
- [14] Prajapati, Purohit, Sharma, Kumar. A Handbook of Medicinal Plants: A Complete Source Book; 1st ed; Agrobios ( India ), Jodhpur, 2003:474.
- [15] Prajapati, Purohit, Sharma, Kumar. A Handbook of Medicinal Plants: A Complete Source Book; 1st ed; Agrobios ( India ), Jodhpur, 2003:318.
- [16] Morton JP, Malone M. H. Evaluation of vulnerary activity by an open wound procedure in rats. Arch. int. Pharmacodyn 1972 1: 117-126.
- [17] Raju S. S., Kulkarni DR. Vitamin A reverses the wound healing suppressant effect of cyclophosphamide. Indian J. pharmac. 1986 18:154-157.
- [18] Bairy K. L., Somayaji S. N., Rao C. M. An experimental method to produce partial thickness burn wound. Indian J Exp Biol 1997; 35:70-2.
- [19] Ramakrishnan K. M., Rao D. K., Doss C. R., Mathivanan T, Manokaran G et al. Incidence of burn wound sepsis in 600 burned patients treated in a developing country. Burns 1985; 11:404-7.
- [20] Wang W. D., Ngao L., Guang X, Ya-Pin Z. Anaerobic infections of burns. Burns 1985; 11:192-6.
- [21] Ramakrishnan K. M, Jayaraman V, Ramachandran K, Mathivanan T. The management of anaerobic infections in extensive burns. Burns 1986; 12:270-2.