

Effect of Retinoic Acid on Fetus Reproductive Organ Mice (*Mus musculus*) Swiss Webster

Yulia Irmidayanti

Abstract—Retinoic acid is like a steroid hormone that plays a role in embryo formation, proliferation of spermatogonia cells, epithelial cells differentiation and organogenesis. Retinoic acid can influences seminiferous tubule formation during embryonic testis development and also play a role in the regulation of ovarian function and female reproductive tract by suppressing the hormones FSH receptor expression. The excessive use of retinoic acid caused abnormalities in the fetus. The result showed that there is the influence of retinoic acid on the developmet of mice fetal testes, for examples disruption of the formation of seminiferous tubules and tubules seemed to be hollow, spermatogonia cells are relatively few in number and caused Leydig cells count relatively more. While in the female fetus does not caused the formation of primordial follicles and disrupted the development of germinal epithelial cells of fetal ovaries of female mice (*mus musculus*) Swiss Webster.

Keywords—Retinoic acid, Leydig cell, Spermatogonia cells, Seminiferous tubules, Primordial follicles

I. INTRODUCTION

RETINOIC acid is the oxidized form of Vitamin A, is the acid form of vitamin A, is a prescription drug commonly used to treat acne and aging skin. It is available as a cream or gel. Vitamin A is one vitamin, is needed by human, because the benefits have been known in general as preventing myopic eyes diseases, bone growth, and helps the development of the embryo. In addition, vitamin A also play a role in the function and structure of epithelial cells in differentiation and proliferation [1].

The use of drugs and chemicals material during pregnancy will affect the development of the embryo in the uterus and during the perinatal period can cause changes in the structure and function of organs in the fetus. Vitamin A is one chemical causes developmental abnormalities when adminis-tered at high doses. The active metabolite of vitamin A has a role in cell differentiation, fetal growth, and development of the Reproductive system. Retinoic acid are known to have a very important role in regulating normal growth and maintain differentiation in adult organisms [2]. It has been reported by Yasuda [3], that retinoic acid has a major teratogenic effects in mice. Other studies have also shown that retinoic acid in supplement form to 3×10^{-8} M/10-6 AllTrans or 9-Cis for 75 hours in culture taken from one every fetal rat testes, affecting the development of Leydig cells, basal cells, and sertoli cells and stimulate the secretion of of the hormone testosterone [4]. We have also made a study of mice with retinoic acid a dose 75 and 100 mg / kg body weight.

Yulia Irmidayanti, Biology Departement, Jakarta State of University, Faculty of Mathematic and Science, Jln Pemuda No. 10 Jakarta, Indonesia, corresponding author: +62 21 4894909; email: irmidayanti@yahoo.com; irmidayanti@unj.ac.id.

The results obtained do not affect the mice's developments, given the almost lethal dose used. Also, the results of research [5], with coculture technique teniques in vitro, has also been shown that retinoic acid affects the survival and proliferation of PGC (Primordial Germ Cell). Several previous studies reported indications that retinoic acid inhibits transcription of the FSH receptor gene [6]. This is evident of the research, that the gene for the FSH receptor is inhibited by the presence of retinoic acid in primary granulosa cells of rat and pig, which means that retinoic acid and its receptors directly involved in the suppression of FSH receptor expression. Based on research has been done by Livera 2001 in culture, [3], So, it is necessary to further studies in vivo, in order to have a contribution to the healts sciences and pharmacy about the teratogenic effects of retinoic acid on the development of fetal reproductive organs of mice (*Mus musculus*) Swiss webster with a dose of 40 mg/kg body weight, in different days of pregnancy at GD-13 to 16.

II. MATERIALS AND METHODS

A. Experimental Animals and Sample Collection

Swiss wesbter mice were used as experimental, from University of Indonesia. Rearing the animals was done in a room at 23-27°C and 83% humidity. Food and water were given ad libitum. When female mice achieved their sexual maturity (10-12 weeks old), they were mated with a male (1:1). A vagina plug detected the following morning was defined as day 0 of gestation day [7].

B. Methods Staining

At the age of the 18th day of pregnancy, the dams mice treated with subcutaneous injection dose of 40 mg / kg body weight per day, during the 13th day of pregnancy until 16. The dams of mice were killed by cervical dislocation at GD-18. The dams mice were cut opened, next uterus was taken and were opened. Then a live fetus was weighed and fixed in Bouin solution for 2 weeks. In Fetal surgery, the dorsal part of fetus body, contain ovaries taken to be done in the oven infiltration, embedding, section 5-7 μ m with a rotary microtome, and then stained with Hematoxylin Eosin [8].

In this study, qualitative observations are histological cross section fetal ovaries and testes of mice, by observing the state of male and female sex cells, and Leydig cells.

III. RESULT

In histological preparations of fetal testes of mice (*Mus musculus*) control, seem to have testicular germinal epithelium layer and the tunica albuginea is a dense connective tissue fibroelastis. Seminiferous tubules havenot formed hollow and the boundary between these seminiferous tubules was clear. In

histological cross section was shown the number of seminiferous tubules relatively more than controls. Number of spermatogonia cells in the seminiferous tubules are also relatively more. On the inside of the seminiferous tubules begin to look no hollow. Leydig cells are found in between the tubules, seminiferous tubules appear to be relatively small (figure 1).

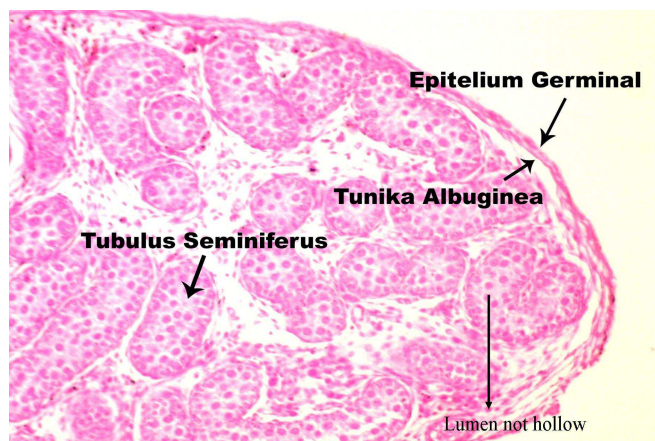


Fig. 1 Histological cross section of fetal testes mice (*Mus musculus*) SwissWebster at GD-18 days from dams were injected retinoic acid at a dose of 0 mg/kg bodyweight on pregnancy day 13 to 16. (enlargement: 10X100)

In the fetal testis histological cross section treated mice, it appears that the testes have a layer that is composed of the tunica albuginea and germinale epithelium, but in histological treatment (figure 2) seems not as clear as seen in controls.

The seminiferous tubules in treatment, have been developmental disorder and boundary formation between the seminiferous tubules is not clearly visible, and began to hollow. The number of seminiferous tubules appear to be relatively less, with the number of spermatogonial cells contained within the tubules, relatively few, compared with controls. Histological structure of the fetal testis show a difference with the control treatment, ie on the tubule and tissue interstitialnya (figure 2) On the inside of a disturbed formation of the seminiferous tubules, encountered a number of spermatogonia cells are relatively fewer. Between seminiferous tubules, Leydig cells with a number of relatively more, compared to controls.

Cross section of fetal ovary controls, consisting of the medulla and the cortex, but the limit of the two parts are not yet clear. Medulla was built by connective tissue containing blood vessels.

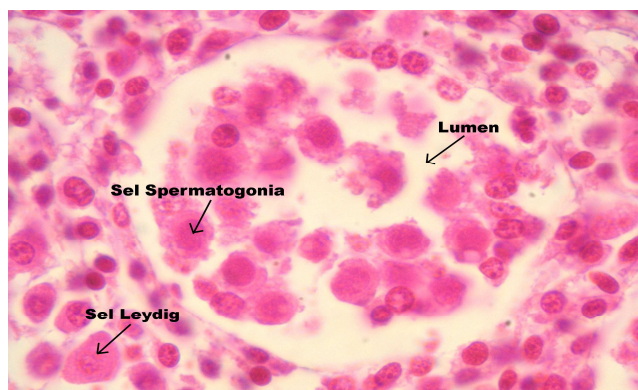


Fig. 2 Histological cross section of fetal testes mice (*Mus musculus*) SwissWebster at GD-18 days from dams were injected retinoic acid at a dose of 40 mg/kg body weight on pregnancy day 13 to 16. (enlargement: 10X100)

Part of the cortex is the part that consists of primordial follicles and stroma. Primordial follicles consists of the oocyte nucleus large round, little cytoplasm, and follicular cells surrounding flat-shaped (figure 3). The number of follicle cells surrounding the oocyte consists of 2 to 3 cell follicles. Histological structure of the fetal ovary treated mice showed a difference with the control. In the treatment of ovarian histological slide, border between the cortex and medulla have started to appear. Although not found the primordial follicles, but many found oogonia cells and degeneration of the relatively small number of follicles. Cell nuclei appear smaller than control, little cytoplasm (figure 4).

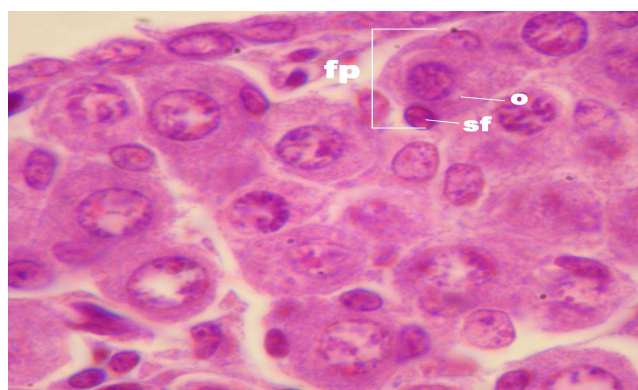


Fig. 3 Histological cross section of fetal ovaries of female mice from dams that injected retinoic acid with doses of 0 mg/kg subcutaneously on the 13th day of pregnancy until the 16th. fp: primordial follicles, O: oocyte, sf: follicle cells, enlargement 1000 x

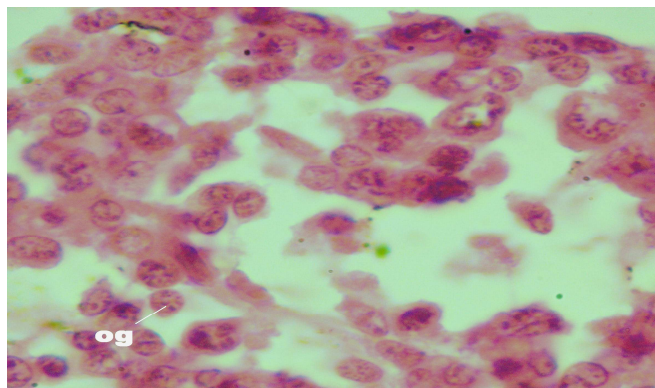


Fig. 4 Histological preparations of fetal ovaries of female mice from dams injected with retinoic acid at doses of 40 mg/kg in the subcutaneous on the 13th day of pregnancy until the 16th. P: treatment, og: oogonia (magnification 1000x)

IV. DISCUSSION

Histological observations of testes can be seen that administration of retinoic acid on the number of Leydig cells. From the results of the report [4], that retinoic acid can affect Leydig cells, which can affect the process of cell proliferation. The process of development and differentiation of Leydig cell consists of three stages. The first phase took place on the day of pregnancy 12 to 15. At this stage, Leydig cells are spindle-shaped, transformed into Leydig cells with many cytoplasmic and in the Leydig cells contained free ribosomes and some polisom. The second stage on the 16th until the 19th and final stage on the 19th day of pregnancy until birth. From the research has been done that, that retinoic acid affects the development of Leydig cells, because the number of Leydig cells relatively more than the control. This situation is trigger the development of the seminiferous tubule lumen. Presumably that retinoic acid acts as a steroid hormone, it can stimulate the secretion of gonadotropin, which is necessary for the development of primordial germ cells [9]. Primordial germ cells are formed to support the formation of the lumen of the seminiferous tubules, thus administration of retinoic acid on pregnancy day 13 to 16 can cause the formation of the lumen seminiferous tubules, but the limits of the seminiferous tubules is less obvious. In the dams body, the accumulation of retinoic acid which through the placenta into the fetal body. Toxicity of Retinoic acid occurred after capacity of retinoic acid binding its receptor CRABP was exceed, thus there are a lot of retinoic acid, are not bound to the receptor CRABP [10]. Free retinoic acid can bind to receptors on the cell nuclei of testicular cells to form complex-retinoic acid receptor retinoic acid, which is then attached to specific regions of DNA affect gene transcription, thereby affecting the process of formation of seminiferous tubules. Histological cross section of fetal ovaries female mice (*Mus musculus*) of Swiss Webster was injected retinoic acid, with dose of 40 mg/kg body weight, subcutaneously on GD-13 to 16, showed small amounts of primordial oocytes, but relatively more oogonia compared with controls.

Retinoic acid-RAR complex that binds in the germinal epithelium would affect follicular development, because the

follicles in the ovaries derived from the germinal epithelium lining the ovarian surface [11]. According on Xing research [6], retinoic acid can inhibit gene transcription of the FSH receptor (FSHR), so the FSH hormone that enters the fetal body cannot affect follicular development. This led to the development of follicles regress. This is consistent with the results of research Koshimizu [5], which proved that the administration of retinoic acid in culture medium can increase the number of oogonia. Follicle degenerates, caused by retinoic acid-RAR complex resulting in impaired follicular cell growth even the follicle cells are not formed, thus degenerated oocytes. According on research that [11], follicle degeneration usually characterized among other things granulosa irregular layer of cells and primary oocytes degenerate. Follicle cell nucleus degeneration also has a wrinkled, little cytoplasm and the number of follicle cells with little or none at all. Presumably retinoic acid cause the follicle degenerates. In normal fetal, follicular cells surrounding the oocyte role is to prevent the occurrence of follicular atresia. At the moment the follicles begin to formed, then start estrogen excreted. Presumably retinoic acid inhibits the development of primordial follicle cells, because follicular cells formed at gestation days of 13 days. A conclusion section is not required. Although a conclusion may review the main points of the paper, do not replicate the abstract as the conclusion. A conclusion might elaborate on the importance of the work or suggest applications and extensions.

ACKNOWLEDGMENT

We thanks, This research was done by Research Grant DIKTI Indonesia 2007 and research institutes.

REFERENCES

- [1] Munir, Warrety M. S. 1990. Perkembangan Embrio Ayam (*Gallus gallus*) yang diperlakukan dengan Vitamin A, MSG, dan Kombinasinya. Laporan penelitian. Universitas Andalas, Padang.
- [2] Liss, Allan R. 1987. Recommendations for Vitamin A Use during Pregnancy. *Teratology*. 35:269-275.
- [3] Yasuda, Yoshiko et al., 1986. Development Anomalies Induced by All-trans Retinoic Acid in Fetal Mice Macroscopic Findings. *Teratology*. 34:37-49.
- [4] Livera, G., Fabre, V., Rouiller and R. Habert. 2001. Retinoid Receptors involved in The Effect of Retinoic Acid on Rat Testis Development. *Biology of Reproduction*. 64:1307-1314.
- [5] Koshimizu, Uichi, Miho Watanabe, Norio Nakatsuji. 1995. Retinoic Acid is a Potent Growth Activator of Mouse Primordial Germ Cells In Vitro. *Developmental Biology*: 168:2:683-685
- [6] Xing, Weirong and M. Ram Sairam. 2002. Retinoic Acid Mediates Transcriptional Repression of Ovine Follicle stimulating Hormone Receptor Gene via a Pleiotropic Nuclear Receptor Response Element. *Biology of Reproduction*: 67:204-211
- [7] Rugh, R. 1971. A Guide To Vetebrate Development 6 th. Burgess Publishing Co. USA.
- [8] Conn, H.J. dan M.A. Darrow. 1960. Staining Procedures. The William and Wilkins Co. Baltimore. P.146-147
- [9] Sarmanu. 1988. "Histologis dan Ultras-struktur Testis Tikus Putih yang Diberi Pakan Mengandung Biji Lamtoro Gung". Laporan Penelitian. Surabaya: Universitas Airlangga.
- [10] Granner and Daryl K. 2003. Kerja Hormon, dalam "Biokimia Harper", E/25. Penulis, Robert K. Murray et al., Alih Bahasa: Anna P. Bani dan Tiara M.N.S., Jakarta: Penerbit Buku Kedokteran - EGC.
- [11] Purba, Dameriyani Nathalia. 2004. Pertumbuhan dan Perkembangan In Vitro Folikel Primordial pada Ovarium Mencit Dengan atau Tanpa Vitrifikasi (Skripsi). IPB. Bogor.