

# Virtual Reality for PostCOVID-19 Stroke: A Case Report

Kasra Afsahi, Maryam Soheilifar, Nouredin Nakhostin Ansari

## II. CASE PRESENTATION

**Abstract**—COVID-19 has been associated with stroke and neurological complications. The patient was a 59-year-old male presented with sudden left hemiparesis and diplopia due to cavernous sinus thrombosis (CST) on 28/03/2020. The COVID-19 test was positive. Multislice computerized tomography (MSCT) showed ischemic infarction. He underwent surgical sinectomy 9 days after admission. Physiotherapy began for him on August 2020. Our game-based virtual reality (VR) technology developed for stroke patients was based on upper extremity exercises and function for stroke. After 6 weeks of VR therapy plus conventional physiotherapy exercises (18 sessions, three times per week, 60 minutes each session), there were significant improvements in Brunnstrom Motor Recovery Stage (from “4” to “5”), Fugl-Meyer Scale score of upper extremity section (from 49 to 54), and Modified Barthel Index (from 15 to 18). There were no adverse effects. This case with stroke post COVID-19 due to the CST showed the usefulness of VR therapy used as an adjunct to conventional physiotherapy in improving affected upper extremity.

**Keywords**—COVID-19, stroke, virtual reality, rehabilitation.

## I. INTRODUCTION

THE Coronavirus disease 2019 (COVID-19) is a new viral infection that has caused outbreak of worldwide pandemic with heterogeneous problems. A recent review of 12 case studies reported 47 cases of stroke in COVID-19 patients, 4 case series reported concurrent stroke along with clinical findings on COVID-19, and another case series found that 10 out of 12 had ischemic strokes [1].

CST is an uncommon, cerebrovascular disease with high morbidity and mortality [2]-[4]. Despite the advent of modern antibiotics and anticoagulants provided for CST, the risk of long-term adverse effects, such as diplopia and stroke, remains highly significant [5], [6]. Various studies have found the CST as a serious complication of COVID-19 [7]-[10]. Here, we report a patient with postCOVID-19 stroke and CST.

VR is a relatively new treatment option that may be used in cases with stroke [11] but the outcomes in cases with stroke post COVID-19 are not determined. We report the effects of VR treatments an adjunct to conventional physiotherapy approaches in this case with stroke postCOVID-19 and CST identified with *multislice CT*.

Kasra Afsahi, MD is with Spark Centre, 2 Simcoe St S#300, Oshawa, ON L1H8C1, Canada, ORCID: 0000-0002-5201-8160 (e-mail: kasra.afsahi@gmail.com).

Maryam Soheilifar, MD is with Iran University of Medical Sciences, ORCID: 0000-0002-7654-0658 (corresponding author, e-mail: msoheilifar1@yahoo.com).

Nouredin Nakhostin Ansari, PT, Ph.D is with Professor of Physiotherapy, Tehran University of medical sciences, ORCID: 0000-0003-2742-2273 (e-mail: nnansari40@gmail.com).

The patient is a 59-year-old male admitted to emergency room with fever, chills, headache, malaise, sudden left hemiparesis, and diplopia on 28/03/2020. COVID-19 test was positive. On examination, the vital signs were stable (BP: 125/80; HR: 72/min; RR: 14/min; T: 39). He was conscious. Heart and lung examinations were unremarkable. Abdominal exam was normal. Neurological exam revealed positive Babinski sign and left 6th cranial nerve (abducens) palsy. While right extremities seemed unaffected, the left side was hemiplegic with patient unable to move the affected left arm and leg. Lab test showed leukocytosis (WBC: 19370 per mm<sup>3</sup>), thrombocytopenia (platelets: 75000 per mm<sup>3</sup>), increased liver enzymes (ALT 136 IU/ml), high ESR (92 mm/hour), and high hs-C-reactive protein (CRP). Blood cultures (three samples) were negative.

MSCT showed right putamen and dentate nucleus ischemic infarction, marked mucosal thickening of ethmoidal sinuses, and complete opacification of sphenoidal sinus in favor of severe chronic sinusitis in paranasal sinuses with polyposis. Electrocardiogram (ECG) and chest radiogram (CXR) were normal. Lung CT scan finding was in favor of COVID-19 with about 10% involvement of the lungs. Carotid ultrasounds showed no abnormality. Abdominal and pelvic ultrasound exam showed normal finding but 150cc urinary residue after voiding.

The treatment provided for his COVID-19 was successful as demonstrated on the improvements of respiratory symptoms and blood oxygen. For his CST and stroke, he underwent surgical sinectomy nine days after admission. Pathological microscopic tests showed ‘inflammatory polyps’. He was discharged after three weeks with good general condition, but he still had stroke related hemiparesis. The Fugl-Meyer Scale (FMS) was scored 31 at admission.

Approximately five months after discharge from hospital, he returned to receive physiotherapy for his hemiparesis. Pretreatment, the examination showed left 6th cranial nerve palsy, The Magnetic Resonance Venography (MRV) was normal and there was no CST. Brunnstrom Motor Recovery Stage (BRMS) of left hemiparetic arm was “4” presenting with decline in spasticity and performing some movement combinations out of synergy [12], [13], Stroke-specific FMS to assess motor function, sensation, joint range of motion (ROM), joint pain, and balance was scored 49 out of 66 for upper extremity section indicating severe impairment [14], [15], and 10-item Modified Barthel Index (MBI) to measure the independence in activities daily living (ADL) was scored 15 (minimum score “0” and maximum score “20”) [16].

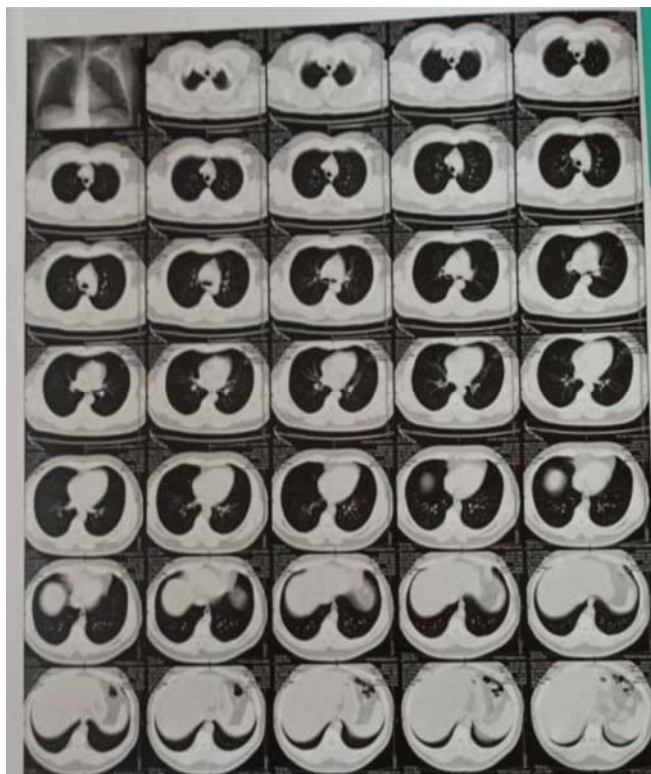


Fig. 1 The Lung CT. Both lungs show normal aeration. Minimal fine ground glass nodular opacities are seen in lower segments of left upper lobe and lingula, suggestive for COVID 19 infection with less than 20 percent lung involvement. Cardiac size is normal. Plural effusion or mediastinal mass or widening is not seen

Physiotherapy program was commenced for him on August 2020 in Tabassom Stroke Rehab Center, Tehran Iran. Our game-based VR system was developed based on upper extremity physiotherapy exercises for post stroke patients to increase the active, voluntary movement of the upper extremity joints and improve the function. The conventional program was initiated with active exercises, shoulder sanding for joint ROMs, walking shoulder, shoulder wheel, and combination movements of shoulder, elbow, and wrist joints, alternative flexion-extension, pronation-supination movements, Pegboard and Purdo pegboard exercises. Also, fine movements included smart gloves, biofeedback, finger ladder, and writing. The difficulty of the game increased at each stage of the practice with progress in patient performances.

After 6 weeks of VR therapy and conventional physiotherapy (18 sessions, three times per week, 60 minutes each session), the upper extremity function was improved with the FMS score increasing from 31 to 54 points. The BRMS improved from "4" to "5" stage. MBI of independence in ADL improved from "15" to "18".

The other MR findings are shown in Fig. 3.

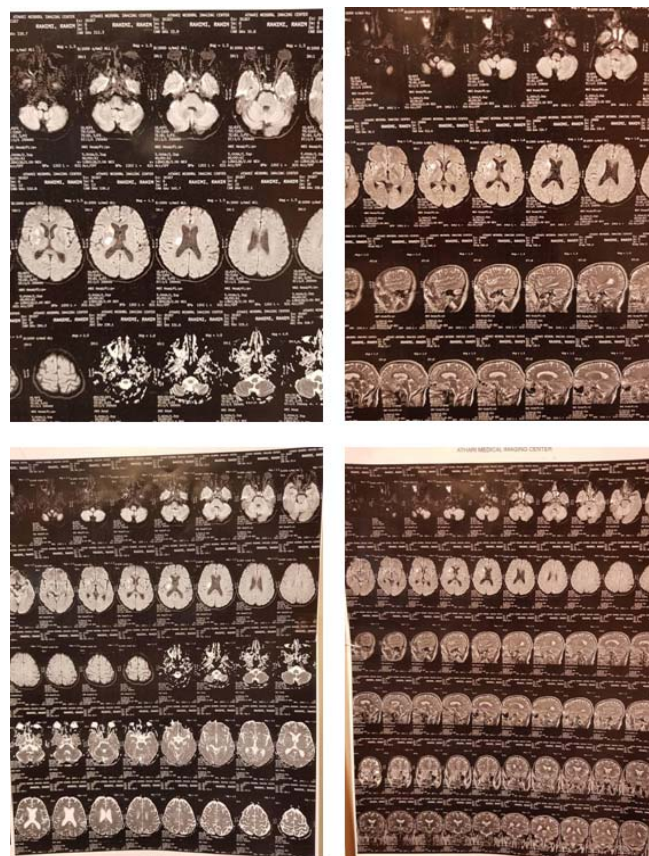


Fig. 2 Abnormal signal intensity at DWI at right periventricular and subcortical of frontal lobe more compatible with acute ischemia in right upper picture and prominence of the ventricular and sulci pattern in left upper picture and slight signal hyper-intensity in the periventricular white matter and centrum semioval in right lower picture and 4th ventricle in midline and posterior cranial fossa with normal limits in left lower picture

After 6 weeks of VR therapy plus conventional rehabilitation (18 sessions, three times per week, 60 minutes each session), there were significant improvements in Brunnstrom Recovery Stage (from "4" to "5"), FMS upper extremity section (total score 66; from 49 to 54), and 10-item MBI was 15 (minimum score "0" and maximum score "20") [16]. There were no adverse effects.

### III. DISCUSSION

In this case report, we presented the successful outcomes for application of VR therapy with conventional physiotherapy in a post COVID-19 stroke patient with CST. VR showed good outcomes without adverse effects in our case with stroke after COVID-19. The previous studies indicate the efficacy and safety of different forms of VR therapy as an effective modality for the rehabilitation of affected upper extremity after stroke [17]-[19]. However, there are scarce data on VR-based therapy on patients with stroke post COVID-19. As far as we know, this case report is the first that report the efficacy of VR based therapy in COVID-19 related stroke.

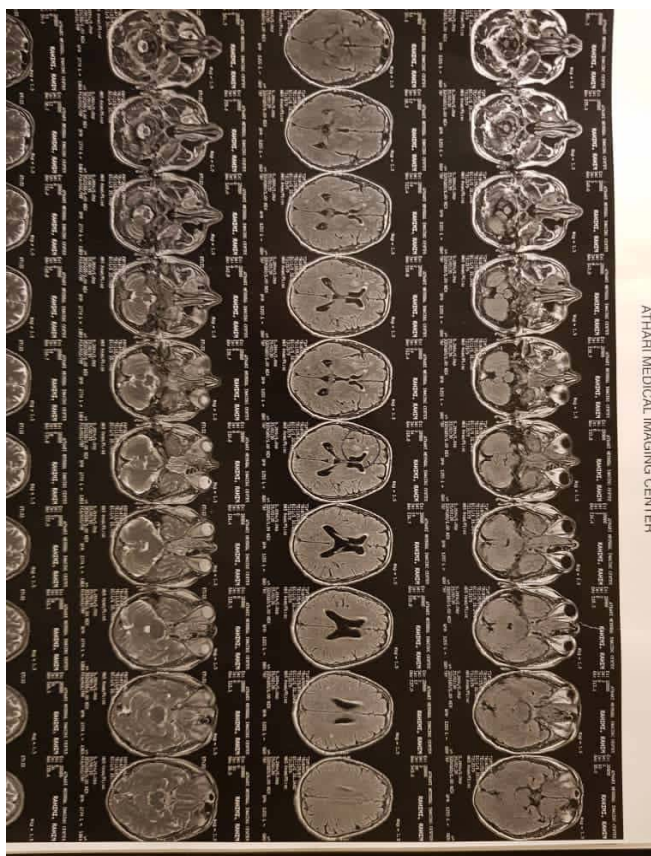


Fig. 3 Remaining less important MR imaging

The outcomes of this case report revealed that a stroke patient post COVID-19 benefited from the VR treatment. The improvements in motor recovery reflected in BRMS and FMS scores might be explained by enhanced stimulation through interactions with virtual environment that led to the activation of affected muscle groups and consequently motor improvements in affected upper extremity. As well, the VR therapy probably improved the upper extremity motor function through massed practice and enhanced visual and auditory feedback [20]. Considering psychological problems observed in people post COVID-19, the adherence of the patient to VR therapy program in this case could be from the joy and fun associated with this kind of treatment that motivated him to achieve his goal in the improvement of affected extremities. The increase in FMS score post treatment was greater than clinically importance differences of 4-points in patients with stroke [21].

Improvement in ADL is due to improvements in motor recovery stage in upper extremities and there was significant decrease in spasticity and the ability for various movement combinations. It follows that the further improvements in spasticity and mobility led to a greater independence in self-care and ADL in this patient with post COVID-19 stroke.

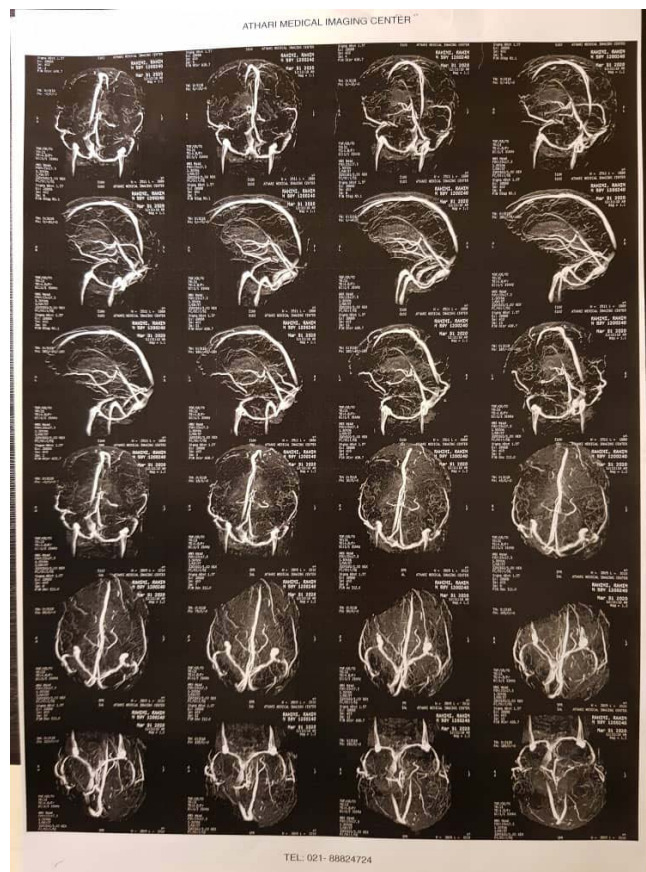


Fig. 4 The superior sagittal sinus and the cortical veins appear normal in diameter and no obstruction of venous flow and normal internal cerebral vein and straight sinus appear normal. There is normal visualization of lateral and sigmoid sinuses. At present no sinus thrombosis is defined

In conclusion, our case demonstrates that the COVID-19 may present with CST resulted in stroke. The VR therapy applied with conventional physiotherapy approaches provides an evidence that the VR based rehabilitation is a promising modality for treating motor deficits of the affected upper extremity after post COVID-19 stroke. Further research is required to verify the outcomes observed in this case report considering the vigorous, randomized controlled trial to be certain of the benefits of VR.

#### REFERENCES

- [1] Reddy ST, Garg T, Shah C, Nascimento FA, Imran R, Kan P, Bowry R, Gonzales N, Barreto A, Kumar A, Volpi J, Misra V, Chiu D, Gadhia R, Savitz SI. Cerebrovascular Disease in Patients with COVID-19: A Review of the Literature and Case Series. *Case Rep Neurol.* 2020 Jun 11;12(2):199-209.
- [2] Geng B, Wu X, Malhotra A. Septic cavernous sinus thrombosis-Case series and review of the literature. *Clin Neurol Neurosurg.* 2020 Oct;197:106092.
- [3] van der Poel NA, Mourits MP, de Win MML, Coutinho JM, Dikkers FG. Prognosis of septic cavernous sinus thrombosis remarkably improved: a case series of 12 patients and literature review. *Eur Arch Otorhinolaryngol.* 2018 Sep;275(9):2387-95.
- [4] Bhatia H, Kaur R, Bedi R. MR imaging of cavernous sinus thrombosis. *Eur J Radiol Open.* 2020 Mar 3;7:100226.
- [5] Weerasinghe D, Lueck CJ. Septic Cavernous Sinus Thrombosis: Case Report and Review of the Literature. *Neuroophthalmology.* 2016 Oct

- 19;40(6):263-276.
- [6] Luo Y, Tian X, Wang X. Diagnosis and Treatment of Cerebral Venous Thrombosis: A Review. *Front Aging Neurosci.* 2018 Jan 30;10:2.
- [7] Hemasian H, Ansari B. First case of Covid-19 presented with cerebral venous thrombosis: A rare and dreaded case. *Rev Neurol (Paris).* 2020 Jun; 176(6):521-523.
- [8] Hughes C, Nichols T, Pike M, Subbe C, Elghenzai S. Cerebral Venous Sinus Thrombosis as a Presentation of COVID-19. *Eur J Case Rep Intern Med.* 2020 Apr 29;7(5):001691.
- [9] Tu TM, Goh C, Tan YK, Leow AS, Pang YZ, Chien J, Shafi H, Chan BP, Hui A, Koh J, Tan BY, Umapathi NT, Yeo LL. Cerebral Venous Thrombosis in Patients with COVID-19 Infection: a Case Series and Systematic Review. *J Stroke Cerebrovasc Dis.* 2020 Dec;29(12):105379.
- [10] Shakibajahromi B, Borhani-Haghighi A, Haseli S, Mowla A. Cerebral venous sinus thrombosis might be under-diagnosed in the COVID-19 era. *eNeurologicalSci.* 2020 Jul 15;20:100256.
- [11] Liao W, Liu Y, Gu W, Yang J, Chen C, Liu F, Zeng F, Wang X. Cerebral Venous Sinus Thrombosis: Successful Treatment of Two Patients Using the Penumbra System and Review of Endovascular Approaches. *Neuroradiol J.* 2015 Apr;28(2):177-83.
- [12] Brunnstrom S. *Movement therapy in hemiplegia: A neurophysiological approach.* New York: Harper & Row; 1970.
- [13] Naghdi S, Ansari NN, Mansouri K, Hasson S. A neurophysiological and clinical study of Brunnstrom recovery stages in the upper limb following stroke. *Brain Inj.* 2010;24(11):1372-8.
- [14] Fugl-Meyer AR, Jääskö L, Leyman I, Olsson S, Steglind S. The post-stroke hemiplegic patient. I. a method for evaluation of physical performance. *Scand J Rehabil Med.* 1975;7(1):13-31.
- [15] Gladstone DJ, Danells CJ, Black SE. The Fugl-Meyer assessment of motor recovery after stroke: a critical review of its measurement properties. *Neurorehabil Neural Repair.* 2002 Sep;16(3):232-40.
- [16] McDowell I, Newell C. *Measuring Health - A Guide to Rating Scales and Questionnaires Second Edition.* Oxford University Press. 1996. pages 56-63
- [17] Lee HS, Park YJ, Park SW. The Effects of Virtual Reality Training on Function in Chronic Stroke Patients: A Systematic Review and Meta-Analysis. *Biomed Res Int.* 2019 Jun 18;2019:7595639.
- [18] Yamato TP, Pompeu JE, Pompeu SM, Hassett L. Virtual Reality for Stroke Rehabilitation. *Phys Ther.* 2016;96(10):1508-1513.
- [19] Henderson A, Korner-Bitensky N, Levin M. Virtual reality in stroke rehabilitation: a systematic review of its effectiveness for upper limb motor recovery. *Top Stroke Rehabil.* 2007;14(2):52-61.
- [20] Shahmoradi L, Almasi S, Ahmadi H, Bashiri A, Azadi T, Mirbagherie A, Ansari NN, Honarpishe R. Virtual Reality Games for Rehabilitation of Upper Extremities in Stroke Patients, *J Bodyw Mov The.* 2020 In press.
- [21] Page SJ, Fulk GD, Boyne P. Clinically important differences for the upper extremity Fugl-Meyer Scale in people with minimal to moderate impairment due to chronic stroke. *Phys Ther.* 2012;92:791-798.