

Erythema Multiforme Exudativum Major Caused by Isoniazid Hypersensitivity in a Child

Azwin Lubis, Rika Hapsari, Zahrah Hikmah, Anang Endaryanto, Ariyanto Harsono

Abstract—Erythema Multiforme Exudativum Major (EMEM) is one of the drug allergy diseases. Drug allergies caused by isoniazid rarely causes EMEM. Cutaneous reactions caused by isoniazid were obtained in 0.98% of patients, but the precise occurrence of Steven Johnson's Syndrome (SJS) and Toxic Epidermolysis Necrolisis (TEN) due to isoniazid is not known for certain. We present this case to show hypersensitivity of isoniazid in a child. Based on the history of drug intake, physical diagnostic tests, drug elimination and provocation; we established the diagnosis of isoniazid hypersensitivity. The child showed improvement on skin manifestation after stopped isoniazid therapy.

Keywords—Erythema Multiforme Exudativum Major, hypersensitivity, elimination test, provocation test.

I. INTRODUCTION

ISONIAZID is a component of first-line treatment for active TB and administered as well for treatment of latent TB. Isoniazid hypersensitivity is a rare occurrence and known to be the least toxic among the antituberculosis drugs. Isoniazid is reported less frequently in skin reactions [1], [2]. Drug eruptions could manifest in various form, like a makulopapular erythematous, lichenoid drug eruptions, haematological reactions, and SJS/TEN [3].

According to the World Allergy Organization, drug allergy occurs in 3% to 6% of all admissions and 10% to 15% of hospitalized patients [4]; unfortunately, the factual drug allergy prevalence among adults and children in the community is still unidentified [5]. Isoniazid-associated cutaneous reactions were noted in 0.98% of patients [6]. The exact prevalence of SJS and TEN caused by isoniazid has not been established yet, probably it seems to be infrequent [1].

Drug allergy is an immunologically mediated response to a pharmaceutical and/or formulation agent in a sensitized person [7]. Drug allergy may occur in the form of immediate or non immediate (delayed) hypersensitivity reactions. Immediate reactions are usually IgE-mediated whereas non-immediate hypersensitivity reactions are usually non-IgE or T-cell mediated. The clinical manifestations of drug allergy may be cutaneous, organ-specific (hepatitis, interstitial nephritis), systemic (anaphylaxis, drug induced hypersensitivity syndrome) or various combinations of these [8].

Diagnostic procedures in drug allergy diagnosis can be classified into the patient's history, *in vivo* skin testing, *in vitro* laboratory tests, drug elimination and provocation tests. It is difficult to established diagnosis of drug hypersensitivity.

Azwin Lubis is with the Airlangga University, Indonesia (e-mail: azwinlubisdr@gmail.com).

A history of drugs consumption could not be reliable, because often many of the drugs are consumed at once. Reagents test, both *in vitro* and *in vivo* is still not standardized. Provocation test is not practical and probably could harm the patient, and it may also not be sensitive if various important factors are missing during the implementation of the procedure [9].

Patients who experience these symptoms need appropriate and rapid recognition to avoid prolonged sequels, and may not be exposed again with the same drug. There is no standardized protocol for drug hypersensitivity reactions; nevertheless, some of the latest studies suggest that patch testing could be helpful. Neither *in vitro* tests nor *in vivo* tests like specific skin tests, as a supporting examination, are yet available to establish isoniazid as a cause of drug hypersensitivity. In some circumstances, like undergoing TB treatment, graded challenges could be indicated to establish or exclude drug hypersensitivity [10].

The purpose of this case is to present Isoniazid hypersensitivity in a child focusing on diagnosis.

II. CASE REPORT

A girl, 13 years old was brought into the Allergy and Immunology outpatient clinic at Dr. Soetomo Surabaya Hospital with the chief complaint of an erythematous rash on her hands that had appeared four days prior. The rash was found on both hands and had spread in all over the body especially the neck, trunk and limbs. The patient complained of feeling itchy and also had developed mouth ulcers.

The history patient shows she was admitted in December 2015 with Meningoencephalitis tuberculosis. Treatment began with combined TB drugs (isoniazid, rifampicin, pyrazinamide) and etambutol for 1 month. She was given a tuberculostatic treatment package of isoniazid, rifampicin, pyrazinamide 6 tablets each day, etambutol 620 mg each day, and prednison commencing on December 5, 2015. The patient had no history of taking any other drugs or any allergic manifestations. There was no history of drug allergy in her parents too.

Local examination revealed a rash on the trunk, upper and lower extremity, there were purpuric rash, redness, target lesions, while there were no squamae, no crustae, and Nikolsky sign was negative. Lip mucous was involved, while there were no genitalia and conjunctiva mucous involvement (Fig. 1). Laboratory examination revealed a normal result.

This patient was assessed as EMEM. The diagnoses were assessed from history taking and physical examination. The patient was planned for hospital admission, but unfortunately the family refused. So, the patient was given medical

treatment with cimetidine 200 mg two times daily, cetirizine 10 mg daily, and all the tuberculosis regiments were stopped.

The patient was given four kinds of drugs, etambutol, isoniazid, rifampicin and pyrazinamide. In practice, it is often difficult to determine which of the anti-tuberculosis drugs as the cause of allergic drug reaction. In order to determine which of the drugs caused the allergy, and elimination test was implemented. It is usually not possible to defer TB treatment for 4-6 weeks, so the elimination test was only conducted for a week. Provocation test was continued after the elimination test.

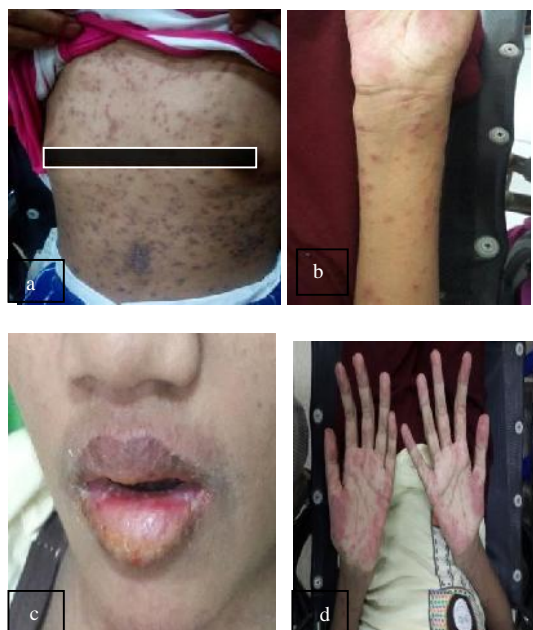


Fig. 1 Patient when first came in Allergy and Immunology outpatient clinic (a) Maculopapular rash with target lesion on the trunk. (b) Maculopapular rash on extensor extremities. (c) Cheilitis as a manifest of mucous involvement. d. Maculopapular rash on palm

All antituberculosis drugs were stopped for one week until the erythematous rash subsided. After recovery, isoniazid was continued and within 36 hours of the first isoniazid tablet being ingested, the patient again complained of similar symptoms like generalized pruritus, with erythema of the face, trunk, and limbs. Isoniazid was stopped and she was followed up at the outpatient clinic with advice to continue Rifampicin for a week and Ethambutol for the next week. No untoward reaction was seen up to a month of follow up (Fig. 2).

After, provocation test was conducted for each of the tuberculosis regiments, and the patient's working diagnosis was assessed as EMEM caused by isoniazid hypersensitivity.

III. DISCUSSION

The common causes of erythematous rash are numerous. It can be caused by atopic dermatitis, contact dermatitis, infection or drug allergy [11]. From the patient history taken there was no previous history of rashes, no sneezing in the morning, and no family atopy history, so we can exclude atopic dermatitis. The patient also has no history of using

topical medicamentosa, so we can exclude contact dermatitis. The patient has no fever and no enlargement of the lymph nodes in the preauricular, so we excluded infection as the cause of erythematous rash. The patient took anti tuberculosis drug regiments, and still at the beginning of the intensive phase. The tuberculosis regiment consisted of isoniazid, rifampicin, pyrazinamide, and etambutol, added with prednison.

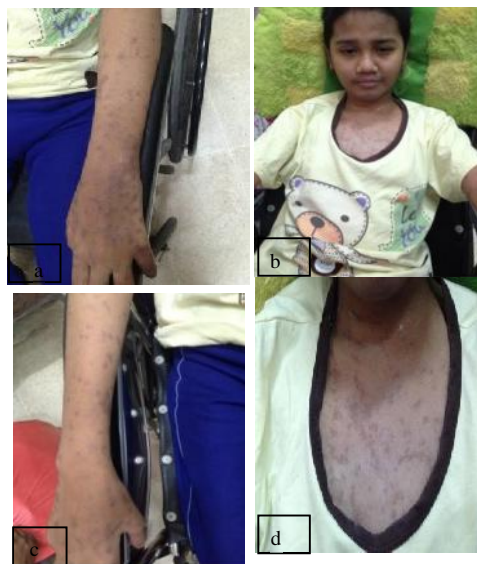

Fig. 2 A week after Isoniazid was stopped. (a) She came to outpatient clinic with good condition. (b) Maculopapular rash with target lesion on the trunk was improved. (c) Maculopapular rash on right extensor extremity was improved. (d) Maculopapular rash on left extensor extremity was improved

Adverse drug reactions (ADR) is defined by the World Health Organization (WHO) as an undesirable harmful response to a drug happening at normal doses and used for the prevention, diagnosis or therapy of a disease [11]. Pharmacological classification broadly divides ADRs into two types of reactions: type A and type B. The reactions of type A are pharmacological effects that expectable and dose-related. Type A reactions amounted about 80% of ADRs, such as side effects, secondary effects, toxic effects and drug interactions. Type B reactions are reactions of hypersensitivity which is unpredictable and not related to the drug dose. This reaction shows symptoms at a dose that can be tolerated by normal individuals [12], and account for about 10%–15% of all ADRs [13]. Type B hypersensitivity reactions involving immunological mechanisms are called drug allergies, and type b reactions that do not involve the immunological mechanism are called non-immune hypersensitivity reactions drug reactions. Drug allergies account for about 5%–10% of ADRs [14]. In this case, we classified the patient with ADRs type B.

In type b hypersensitivity, some decisions can be made, drugs must not be repeated after experiencing a life-threatening reaction, but for lighter reactions drug provocation can be selected. For immunologically (allergy) related type B reactions, the choice of therapy depend on the underlying

mechanism. If a valid test for confirmation is available, it can be used to establish the allergic status of the patient. If the test is not available, and the majority is not, some steps can be taken.

The easiest method is drug avoidance, if there is a replacement drug. If a replacement drug is unavailable, a gradual provocation test with the suspected drug can be conducted if the reaction formerly is not life-threatening and not consistent with a reaction associated with IgE. However, if the drug is still needed as the drug of choice in the treatment, the desensitization method can be considered [15].

Allergic reactions to drugs include rashes that are morbilliform or lichenoid (violaceous, flat topped, pruritic papules), flushing, and extremely rarely, SJS [16]. Allergy drug hypersensitivity to TB drugs is not uncommon. The rash commonly occurs within the first week after the drug is consumed and disappears a few days after the drug is discontinued. Drug-induced allergy is hard to differentiate with viral exanthems, but their symptoms may be more dominantly erythematous and itchy. Erythema multiforme is a disease with an acute onset, self-limited, and sometimes may appear again due to hypersensitivity reaction related with infections or drug administration [17].

There are 2 types of erythema multiforme, minor and major. Erythema multiforme minor marked by raised or typical targets, edematous papules distributed on acral area of hands and feet. Symptoms of erythema multiforme major are similar with erythema multiforme minor, plus one or more mucous membranes involvement; detachment of epidermal involves fewer than 10% of the entire surface area of the body [18].

Erythema multiforme is typically rash with peripheral eruptive maculopapular that most often occurs. The rash can recur, especially in the predilection area such as the palms of the hands, soles of the feet, knees and elbows. Erythema multiforme is preceded with the appearance of macular eruption, after the reddish macular lesions develop into papules, with the characteristic of typical target-shaped lesions. Vesicles or bullae or both of them can be found in the middle of the papules. There is also involvement of the mucous membranes of the lips and mouth. The classification of minor or major criteria depends on the degree of disease severity. There are no bullae and systemic symptoms in erythema multiforme with minor criteria, the typical of eruption is limited to the surface of extensor extremities and infrequently includes the mucous membranes. Erythema Multiforme Major often occurs due to drug reactions and there is always involvement of the mucous membranes. The eruption develops into bullous, and there are systemic symptoms. Complications such as stomatitis and cheilitis may cause eating difficulty, and conjunctivitis can cause ulceration and keratitis. A variety of lesions can also appear in the trachea, larynx, pharynx or all of those areas [19]. In this patient, we found erythematous papular rash, target-shaped lesions in the palm, extensor surface of all extremities, and trunk. We did not find any vesicle or bullae lesions, but there were no mucous membranes involved since we found

stomatitis. Thus, this patient was classified into erythema multiforme major.

Nikolsky sign is a skin disorder in which the top layers of the skin slip away from the lower layers when slightly rubbed. The hallmark of which is Nikolsky sign indicated by TEN. TEN is the most serious form on this clinical spectrum. It tends to be a more serious prodromal syndrome, with burning or painful eruptions, and blisters on the skin located symmetrically on the face and upper torso. This eruption rapidly extends to the entire body, more than 30% of body surface area; although it predominates on the trunk and proximal limbs [20]. There were no Nikolsky sign and blisters on this patient.

The prodromal symptoms of SJS are more severe. In addition, symptoms such as vomiting, nausea, pharyngitis, asthenia, arthralgia, and fever can also occur. The involvement of the mucous membranes in SJS can cause various disorders including in the lips and mouth causing disruption of sound production, swallowing disorders, and oral consumption. In conjunctiva, there may be conjunctivitis and symblepharon, and in the genital areas mucosal disorders may occur. Skin lesions are not symmetrical [20]. In this case, only one mucosa was involved.

A diagnosis of drug hypersensitivity should be established through a history of clinical symptoms and physical examination, and then continued with some investigations such as validated skin test, laboratory examination, drug elimination and drug provocation test [21].

A skin test may be used to evaluate drug hypersensitivity, but the value of diagnostic validity has not been further evaluated. It may be that the possible procedures and skin test reagent concentration is still not validated for a wide range of drugs, and also the unavailability of various tests in the Asia Pacific region [9].

Drug provocation test (DPT) is an administration of a drug in a controlled manner and performed under medical surveillance with the aim of establishing the diagnosis of drug hypersensitivity reactions. It is a gold standard in determining positive or negative values to establish the diagnosis of drug hypersensitivity [22].

Due to the rapid onset, the allergic reaction is called immediate hypersensitivity; however, in immediate reactions there is sometimes a long-term onset called late phase reaction. In the immediate phase, allergic skin reactions occur within minutes, then after a few hours and the following day, infiltration by immunocompetent cells occurs and is dominated by eosinophils, neutrophils, macrophages and TH2 [23].

Immediate hypersensitivity is closely related to IgE, and mast cells or basophils act as a main component. The mechanism of the reaction involves the production of specific IgE in response to a particular antigen. Re-exposure to the same antigen leads to the relationship between antigen and mast cell-bound IgE specific and triggering the release of various pharmacologically active substances. Mast cells degranulation can be stimulated by non-IgE-mediated

interactions, reactions that occur are not associated with hypersensitivity, although cause the same symptoms [23].

Based on the onset of time, type IV hypersensitivity is a delayed hypersensitivity reaction, and one of the symptoms is contact dermatitis, where the lesions on the skin are more papular. Damage mechanisms in type IV hypersensitivity involve macrophages and/or monocytes and T lymphocytes. Cytotoxic T cells (Tc) induce damage directly while helper T 1 (TH1) cells 1 produce cytokines that trigger cytotoxic T cells to recruiting and activating macrophages and monocytes as the biggest cause of damage. The type IV hypersensitivity lesions primarily consist of monocytes and T cells. The lymphokines that are often responsible for the type IV hypersensitivity reactions consisted of interleukin-2, TNF alpha/beta, interferon-gamma, monocyte chemotactic factor [24].

IV. SUMMARY

A case of EMEM caused by isoniazid hypersensitivity in a child has been reported. The patient presented with maculopapular rash with target lesion and history of consumed antituberculosis drug regiments.

Diagnostic approach in this case was based on history findings, clinical manifestation, physical examination, elimination test and provocation test. The clinical manifestation on the skin referred to EMEM. We classified this patient as Adverse Drug Reaction Type B (Hypersensitivity). Drug provocation test was done to distinguish which drug caused the allergy in this patient, and it was found that isoniazid was the cause of hypersensitivity.

The patient showed improvement in skin manifestation after the isoniazid therapy was discontinued.

REFERENCES

- [1] Mario Sánchez-Borges, Bernard Thong, Miguel Blanca, Luis Felipe Chiaverini Ensina, Sandra González-Díaz, Paul A Greenberger et al. Hypersensitivity reactions to non beta-lactam antimicrobial agents, a statement of the WAO special committee on drug allergy. World Allergy Organization Journal. 2013. 6:18.
- [2] Bernard Yu-Hor Thong. Update on the Management of Antibiotic Allergy. Allergy Asthma Immunol Res. 2010.2(2):77-86
- [3] Forget EJ, Menzies D. Adverse reactions to first-line antituberculosis drugs. Expert Opin Drug Saf. 2006.5:231-49.
- [4] Bernard Y-H. Thong & Teck-Choon Tan. Epidemiology and risk factors for drug allergy. Br J Clin Pharmacol. 2010.71:5.684-700 (5) Bernard, Tan. Drug Allergies. Worldallergy.org. 2014.
- [6] Tan W. C, Ong C. K, Kand S. C, Razak M. A: Two years review of cutaneous adverse drug reaction from first line anti-tuberculosis drugs. Med J Malaysia. 2007. 62:143-6.
- [7] Roland Solensky, MD, and David A. Khan, MD. Drug Allergy: An Updated Practice Parameter. Joint Council of Allergy, Asthma & Immunology. 2010.105(273).
- [8] Thong BY, Leong KP, Tang CY, Chng HH. Drug allergy in a general hospital: Results of a novel prospective inpatient reporting system. Ann Allergy Asthma Immunol. 2003. 90:342-7.
- [9] Brockow, A. Romano, M. Blanca, J. Ring, W. Pichler, P. Demoly. General considerations for skin test procedures in the diagnosis of drug hypersensitivity. Allergy. 2002. 57: 45-51.
- [10] Greenberger P. A: Drug allergy. Allergy Asthma Proc. 2012. 33:S103-S107.
- [11] Edwards I. R, Aronson J. K. Adverse drug reactions: definitions, diagnosis, and management. Lancet Journal. 2000. 356: 1255-59
- [12] Johansson S. G, Bieber T, Dahl R, et al. Revised nomenclature for allergy for global use. Report of the Nomenclature Review Committee

- of the World Allergy Organization, October 2003. J Allergy Clin Immunol. 2004;113: 832-836.
- [13] Greenberger P. A. 8. Drug allergy. J Allergy Clin Immunol. 2006. 117 (2 Suppl Mini-Primer): S464-S470.
- [14] Francis C. K. Thien. Drug hypersensitivity. MJA. 2006. 185(6);333-38
- [15] Rive, Craig M, Jack Bourke, Elizabeth J. Phillips. Testing for Drug Hypersensitivity Syndromes. Clin Biochem Rev.2013. 1:15-38.
- [16] Centers for disease control and prevention, treatment of tuberculosis, American thoracic society, CDC, and infectious diseases society of America. MMWR. 2003, 52:20-21. No. RR-11.
- [17] Michele, Lamoreux, Marna R. Sternbach, W. Teresa. Erythema Multiforme. Am Fam Physician. 2006.1;74(11):1883-88.
- [18] Labrèze, T. Lamireau, D. Chawki, J. Maleville, A. Taïeb. Diagnosis, classification, and management of erythema multiforme and Stevens-Johnson syndrome. Arch Dis Child. 2000. 83:347-52.
- [19] Harry D. Mckinnon, Thomas Howard. Evaluating the febrile patient with a rash. Am fam physician. 2000. 15:62(4):804-16.
- [20] Kroonen, Lisa M. Erythema Multiforme: Case Report and Discussion. ABFP. 1998. 11(1);63-5.
- [21] Demoly P, Bousquet J. Drug allergy diagnosis work up. Allergy. 2002. 57(Suppl. 72):73-60.
- [22] Aberer W, A. Bircher, A. Romano, M. Blanca, P. Campi, J. Fernandez, et al. Drug provocation testing in the diagnosis of drug hypersensitivity reactions: general considerations. Allergy. 2003. 58: 854-63.
- [23] Goldsby R. A., Kindt T. J., Osborne & Kuby J. Immunology, 5th Edition. 2003.
- [24] Madhu Pruthi. Basic concepts of autoimmunity, hypersensitivity and immunodeficiency disorders. 2007.