

# Thread Lift: Classification, Technique, and How to Approach to the Patient

Panprapa Yongtrakul, Punyaphat Sirithanabadeekul, Pakjira Siriphan

**Abstract**—Background: The thread lift technique has become popular because it is less invasive, requires a shorter operation, less downtime, and results in fewer postoperative complications. The advantage of the technique is that the thread can be inserted under the skin without the need for long incisions. Currently, there are a lot of thread lift techniques with respect to the specific types of thread used on specific areas, such as the mid-face, lower face, or neck area. Objective: To review the thread lift technique for specific areas according to type of thread, patient selection, and how to match the most appropriate to the patient. Materials and Methods: A literature review technique was conducted by searching PubMed and MEDLINE, then compiled and summarized. Result: We have divided our protocols into two sections: Protocols for short suture, and protocols for long suture techniques. We also created 3D pictures for each technique to enhance understanding and application in a clinical setting. Conclusion: There are advantages and disadvantages to short suture and long suture techniques. The best outcome for each patient depends on appropriate patient selection and determining the most suitable technique for the defect and area of patient concern.

**Keywords**—Thread lift, thread lift method, thread lift technique, thread lift procedure, threading.

## I. INTRODUCTION

THREAD lifting is a cosmetic procedure that lifts and realigns sagging tissue, while adding definition to facial contours by using threads that are manufactured from the same materials used in surgery to close wounds. When placed under the skin, they can be used to tighten the tissue and add volume to the area of application. Even though there are many thread lift techniques used in clinical practice, there has not been a comprehensive literature review about thread lift techniques. Therefore, we propose to review the use of thread lift techniques for facial rejuvenation, focusing on the type of thread, patient selection, and how to choose the appropriate technique for the selected patient. We employed the PUBMED and MEDLINE website search engines to retrieve the relevant literature by inputting the following keywords: Thread lift, thread lift method, thread lift technique, thread lift rejuvenation, and thread lift procedure. We included clinical trials, comparative studies, controlled clinical trials, and clinical reviews from January 1970 to October 2015. We read all of the abstracts of the studies and filtered those that were

P Yongtrakul is with Division of Dermatology, Chulabhorn International College of Medicine, Thammasat University, Khlong Luang, Pathumthani, Thailand 12120 (phone: 66909012222; e-mail: bummt@hotmail.com).

P Sirithanabadeekul was with Division of Dermatology, Chulabhorn International College of Medicine, Thammasat University, Khlong Luang, Pathumthani, Thailand 12120 (e-mail: punyaphats.cicm@gmail.com).

P Siriphan is with Pan Rajdhevee Suphannahong Foundation, Bangkok, 10330, Thailand (e-mail: docnong\_2000@hotmail.com).

not relevant to our study topic. We then gathered and read all related full-text research articles and summarized them within this topic review.

## II. LITERATURE REVIEW

### A. Facial Aging

Facial aging reflects a combination of skeletal and connective tissue changes. Alteration in the position of the soft tissue and overlying muscles causes the appearance of aging [1]. Signs of aging include poor definition of the mandibular margin, wrinkles of the forehead, vertical wrinkles in the glabellar area, drooping of the zygomatic malar region, and deepening of the naso-buccal fold. Another main factor in the effect of aging on appearance is gravity, which causes ptosis of the facial soft tissue, such as the downward shift of the malar fat pad that creates hollowness of the mid-facial and infra-orbital area. Consequently, facial rejuvenation should be performed in a vertical direction [2]-[4].

### B. Types of Thread

The types of thread can be divided into three main categories.

#### 1. Mode of Absorption

- 1.1 Absorbable threads including Polydioxanone thread (PDO) [5]-[7], Silhouette Soft thread (Poly-L-lactic acid or sculptra in solid form), and fine thread with bi-directional absorbable cone [8].
- 1.2 Non-absorbable thread including APTOS thread, Contour thread, Silhouette lift thread, Woffles thread (Polypropylene).

#### 2. Barbed and Non-Barbed Thread (Smooth Threads)

##### a) Barbed Thread

There are 3 types of barbed thread [9]-[11]:

- 1) Bi-directional thread (Long suture) are inserted into a hollow needle and then placed in the treated area.
- 2) Uni-directional barbed threads (Long sutures) are designed to be anchored to a fixed structure, such as the deep temporal fascia.
- 3) Cogged Threads (Short sutures): Examples include PDO Uni-directional cogged thread, PDO Bi-directional cogged thread, and PDO Multi-directional cogged thread [12].

##### b) Non-Barbed Threads (Smooth Thread)

There are two types of Non-barbed thread:

- 1) Monofilament Plain: Examples include Miracu plain thread and TR lift thread.
- 2) Monofilament Screw or Spiral: Examples include K2 screw lifting and T Screw lifting thread.

The value of Bi-directional thread over Uni-directional thread, and Non-barbed thread, is that Bi-directional thread cannot move in either direction because of the two-way fixation provided by the barbs. However, if there is asymmetry of the face from the thread insertion, Uni-directional threads or Non-barbed threads allow easier postoperative correction [13], [14].

### 3. Length of Threads

We suggest classifying the thread based on its length, because different lengths are used for different lift techniques such as the Short suture technique and Long suture technique.

3.1 Short suture is defined by any thread shorter than 90 mm in length.

3.2 Long suture is defined by any thread longer than 90 mm in length.

### C. Treatment Algorithm

First, design the treatment technique with a marker or pencil-based drawing. Prescribe prophylactic antibiotics 1 hour before treatment. Use an anti-bacterial product such as chlorhexidine prior to thread insertion. For superficial Plain threads, apply a 7-15% lidocaine cream 45 minutes before the procedure. For cog thread and any long thread (more than 90 mm), local anesthesia, such as 1-2% solution of Lidocaine with Epinephrine (1/200,000), should be injected at the insertion area. Ensure that the threads are cut at the insertion point and the cog ends are submerged underneath the skin, otherwise protrusion may occur. Clean the area and apply ice packs to the thread-treated area following the procedure to minimize edema and bruising.

### D. How to Apply the Thread Lift Procedure

The thread insertion technique can be distinguished into two approaches by the difference in thread length, including a protocol for short suture and a protocol for long suture techniques.

#### 1. Protocols for Short Suture

The protocol for threads shorter than 90 mm, such as Polydioxanone thread (Plain, Screw, Spiral and Cog thread), involves the use of the free floating method. The guidelines below provide the minimum number of threads required for each treatment area. If severe skin laxity or excess adipose tissue is present, more threads can be inserted [15].

##### a) Lower Face Area and Jawline

Step 1. Insert five to 10 Mono Plain or Screw threads for each side as shown in Fig. 1 (A). For skin tightening and rejuvenation, insert the needle into the dermis plane. For lipolysis, insert the needle deeper into the subcutaneous plane.

Step 2. Insert four to six cog threads for each side at insertion point (A), located 1.5 cm pre-auricular and 1 cm below

the lower border of the zygomatic bone, extending down to the superficial musculoaponeurotic system (SMAS) plane [16], [17]. Follow this line until you meet the end-points shown in Fig. 1 (B).

Step 3. Insert two to five Mono Plain or Screw threads in another three directions, as shown in Fig. 1 (C). This step creates a meshwork relative to Steps 1 and 2.

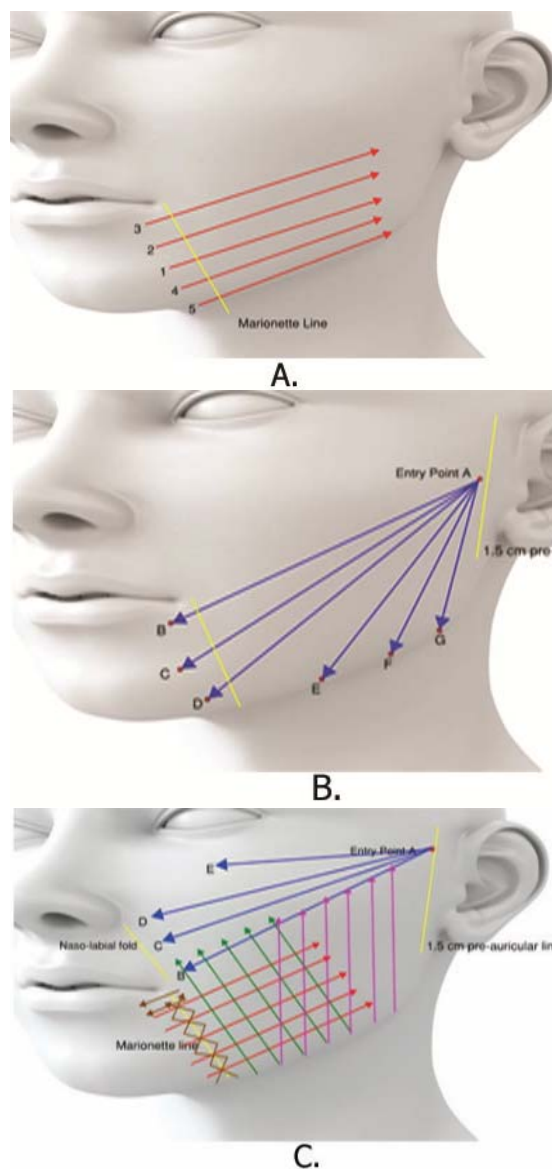


Fig. 1 Short suture techniques for lower face lift: (A) Mono Plain or Screw threads insertion; (B) Cog threads insertion; (C) Mono Plain or Screw threads insertion in another three directions to create a meshwork

##### b) Mid-Face and Cheek Area

Step 1. Insert four to six cog threads for each side, down to the SMAS plane as shown in Fig. 2 (A).

Step 2. Insert five to 10 Mono Plain or Screw threads for each side as shown in Fig. 2 (B).

Step 3. (Naso-labial fold) Insert 3-5 Mono Screw threads for each side. Insert the 1<sup>st</sup> screw thread into the Naso-

labial fold straight, and then insert the 2<sup>nd</sup> to 5<sup>th</sup> thread in a zig-zag fashion [18] (Fig. 2 (C)).

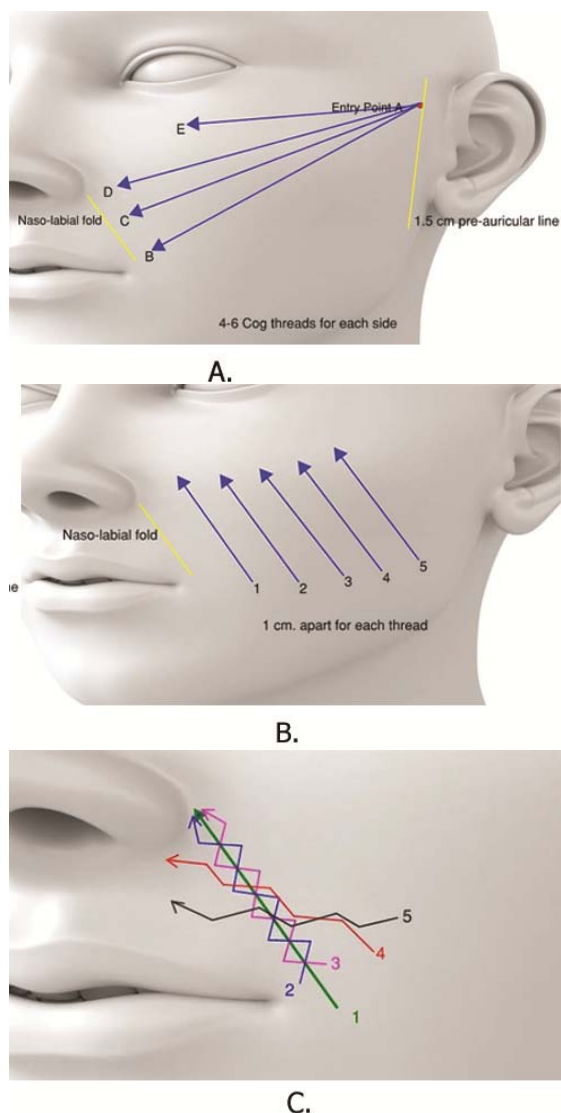


Fig. 2 Short suture techniques for mid-face and cheek area: (A) Cog threads insertion; (B) Mono Plain or Screw threads insertion; (C) Mono Screw threads insertion into the nasolabial fold

#### c) Peri-Ocular Area

- Medial and Lateral eyebrow lift: Insert two to four Cog threads at insertion point (A), located 1 cm below the hairline. Insert the 1<sup>st</sup> Cog thread through sub-dermis ending at point B, 1 cm above the brow, in order to avoid trauma to the temporal branch of the facial nerve.

Once the Cog thread is anchored, slowly retract the cannula and clamp the Cog thread. Insert the 2<sup>nd</sup> Cog thread sub-dermally towards end-point C, 1 cm above the brow and parallel to the lateral canthus line. Clamp both Cog threads together and trim them close to the skin (Figs. 3 (A) and (B)).

- Crows feet: Insert five Mono Plain threads, 30 mm in length using a 31-G needle, into the dermis for each side. Insert the 1<sup>st</sup> to 3<sup>rd</sup> threads in a horizontal direction and the

4<sup>th</sup> and 5<sup>th</sup> threads in a vertical direction to create a meshwork (Fig. 3 (C)).

- Tear trough lift: Select and insert five Mono Plain threads, 30 mm in length using a 31-G needle, into the sub-dermis of the lower eyelid on each side (Fig. 3 (D)).

#### d) Neck Area

Insert 10-15 Mono Screw threads horizontally and 10-15 Mono Plain threads vertically for each side, deep into the sub-dermis [2], [16], [19], [20] (Fig. 4).

#### 2. Protocols for Long Suture

The protocol for thread longer than 90 mm, such as APTOS 2/0, 4/0, Silhouette Lift, Silhouette Soft, or Contour thread.

Most long sutures are barbed, including bi-directional and uni-directional threads. The procedure technique that is usually applied for uni-directional thread is the fixed method (with an anchoring point), while the procedure technique for bi-directional thread is the free-floating method (without an anchoring point). A third type of procedure is a double needle technique that also uses the free-floating method (without an anchoring point). All procedures can be performed under local anesthesia.

For the Fixed method (with an anchoring point), 3-4 mm incisions for insertion of a straight needle are necessary. The incision point should be located at the deep temporal fascia or periosteum so that it can be used as an anchoring point. For lower face and cheek lifting, the anchoring point is made posterior to the frontal and temporal hairline [20], [21]. For neck lifting, the anchoring point is made posterior to the sternocleidomastoid muscle.

#### a) Lower Face Area and Jawline

##### *Technique 1 Lower Face Thread Lift [22], [23]*

Uni-directional threads are recommended. Select two long barbed threads for each side. Tie a knot in the thread at the deep tendon fascia. Insert the needle at the incision point, deep to the SMAS, and at the 2<sup>nd</sup> halfway point the needle should be more superficial, as it moves into the subcutaneous plane. At 1.5 cm medial to the marionette lines, the needle is brought out, leaving the thread in the tissues. Pull the thread lightly and then trim the excess thread (Fig. 5 (A)).

##### *Technique 2 Lower Face Thread Lift*

Bi-directional threads are recommended. Select two bi-directional threads for each side. Make a puncture wound in the pre-tragus area (point A). Insert "a flexible hollow needle" deep to the papillary dermis and then follow the line, maneuvering the needle in a slight zigzag pattern until the tip of the needle passes through the exit point (point B). Insert the thread into the needle and carefully withdraw the needle leaving the thread positioned in the dermis. Pull the thread lightly and then trim the excess thread (Fig. 5 (B)).

##### *Technique 3 Redefinition of the Mandibular Contour*

Select one double needle thread for each side. Insert both straight needles into the sub-dermal layer through two adjacent inlet holes. Follow the line as shown in Fig. 5C. Pull

both ends of the thread and then trim the excess. No sutures are necessary.

**Technique 4 Woffles Lift**

Choose three to four Woffles threads for each side. Make a small incision at point B. Insert the introducer from point A upwards until it exits at point B. Then, remove the stillete and insert one Woffles thread from point B downward to point A

until half of the thread has been inserted. Re-insert the introducer from point C upwards until it exits at point B again. Introduce the other half of the Woffles thread into point B until it exits at point C. Remove the needle, pull the end of the thread firmly while pushing the skin upward in a vertical direction, and then trim the excess thread (Figs. 5 (D)-(F)).

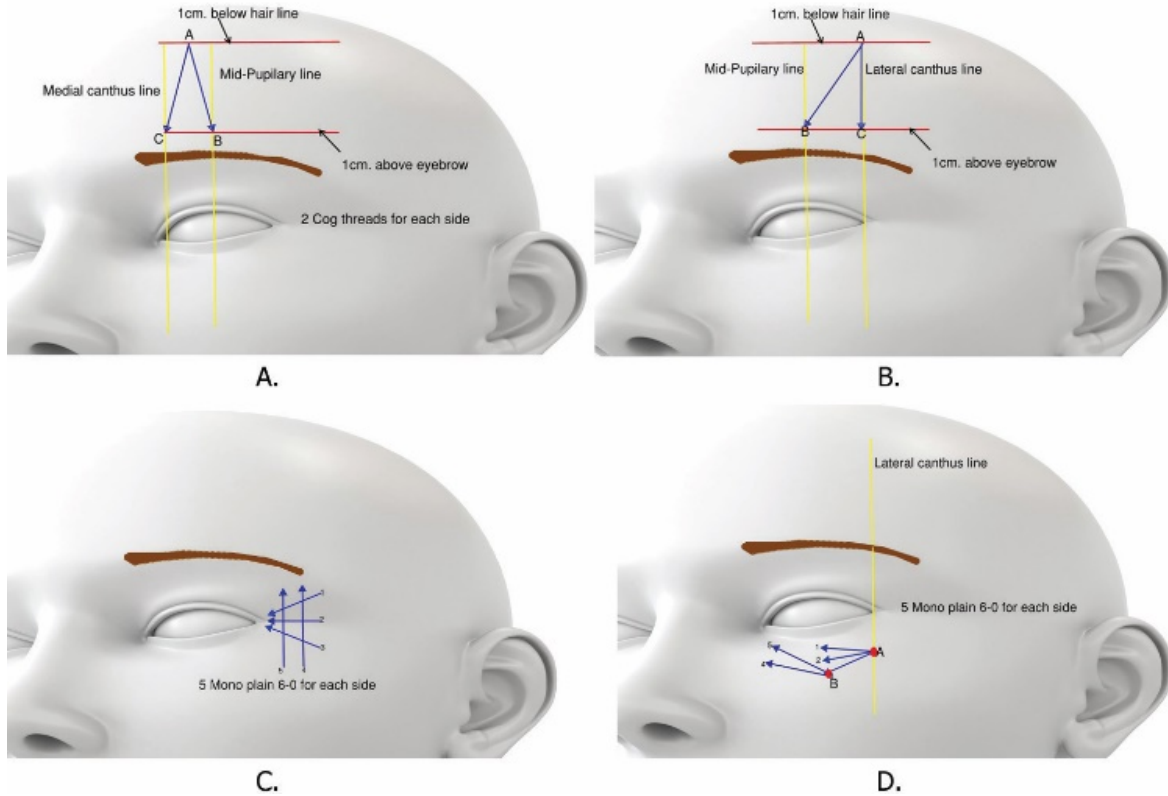


Fig. 3 Eye brow lift: (A) Medial eyebrow lift; (B) Lateral eyebrow lift; (C) Crow's feet; (D) Tear trough

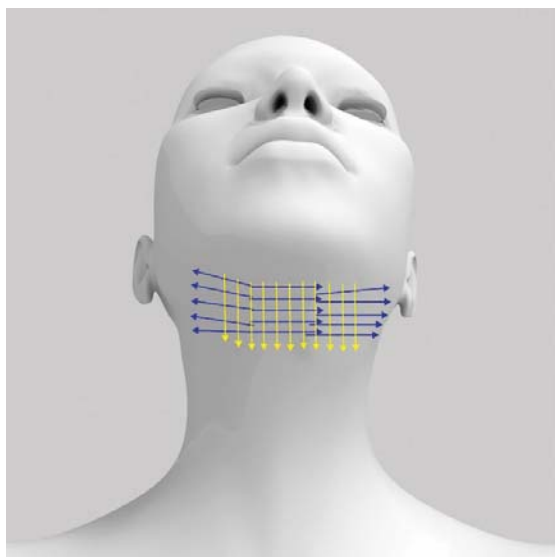


Fig. 4 Short suture technique for Sub-mental fat pad, Double chin, and Skin tightening

**b) Mid-Face and Cheek Area: Malar Fat Pad Lifting**

**Technique 1 Straight Needle with Anchoring Point** [2], [3], [8], [24]-[27].

Choose 3-4 long barbed threads for each side. Make a 1 cm incision. Tie a knot of the thread at the deep tendon fascia. Insert the needle at the incision point. Angle the needle upward from the periosteum to the malar fat pad area. At 1 cm lateral from the naso-labial crease, the needle is brought out, leaving the thread in the tissues. Pull the end of the thread firmly and push the skin of the cheek back over it. Then trim the excess thread (Fig. 6 (A)).

**Technique 2 Curved Needle with Anchoring Point (5 cm or 6 cm Needle with 45 cm Thread)**

Make a 2 mm to 3 mm incision along the "crow's feet" wrinkles (Point 1). Insert the needle at the incision point. Pass the needle through the subcutaneous area along a triangular path to Points 2 and 3 and return to Point 1. At Point 1, the needle is brought out, and threaded back into the wound again. Both ends of the thread are brought together and attached to the orbital periosteum with several knots (Fig. 6 (B)).

*Technique 3 Double needle without anchoring point technique.*

Insert two needles in a single puncture and then separate them from each other. Advance the needles medially in the

direction of the malar fat pad, moving to the surface at the marked points, and then return to the temple area where the threads are anchored to the zygomatic periosteum. No sutures are necessary (Fig. 6 (C)).

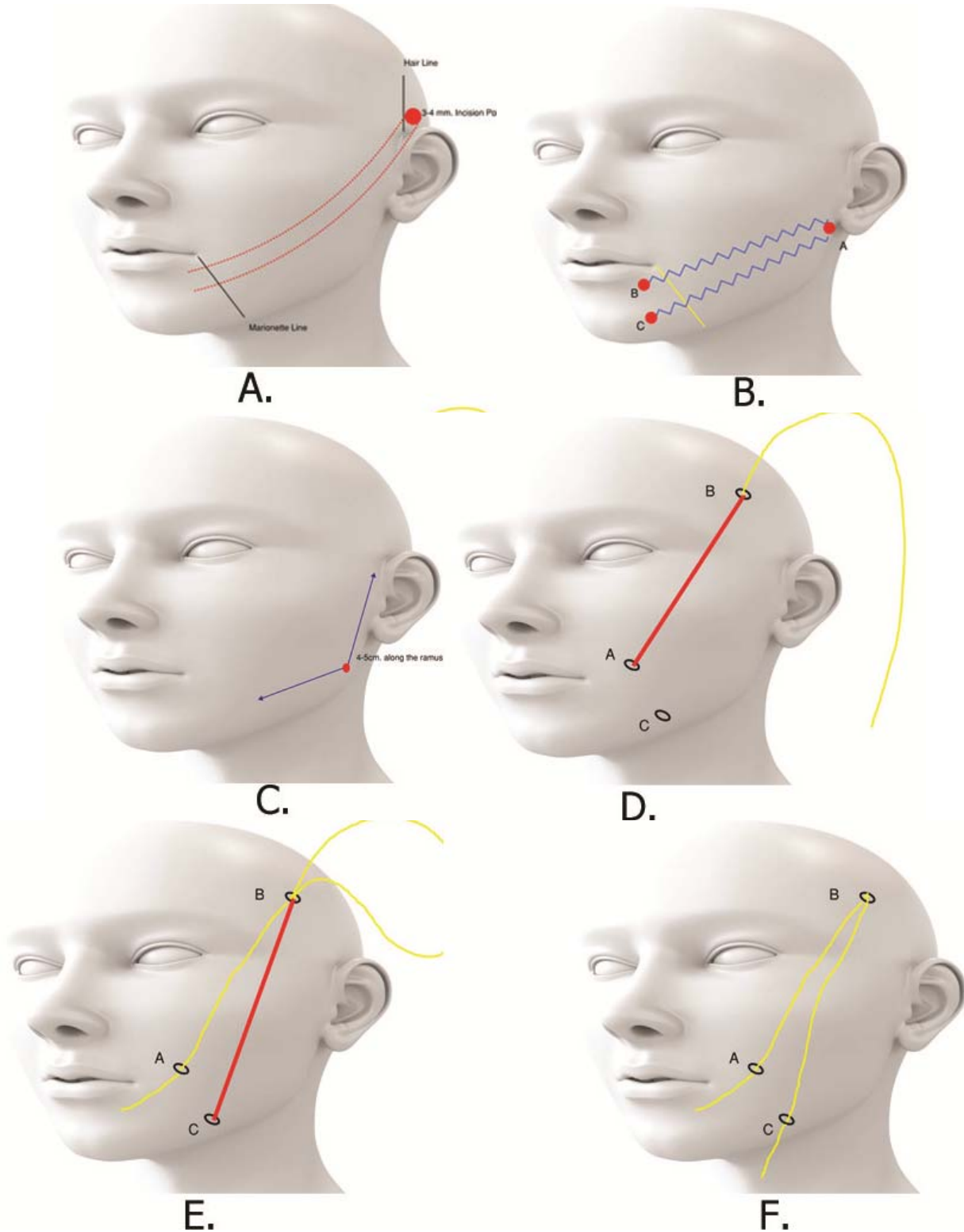


Fig. 5 Lower face lift: (A) Uni-directional thread technique; (B) Bi-directional thread technique; (C) Double needle technique; (D), (E) and (F) Woffles lift technique

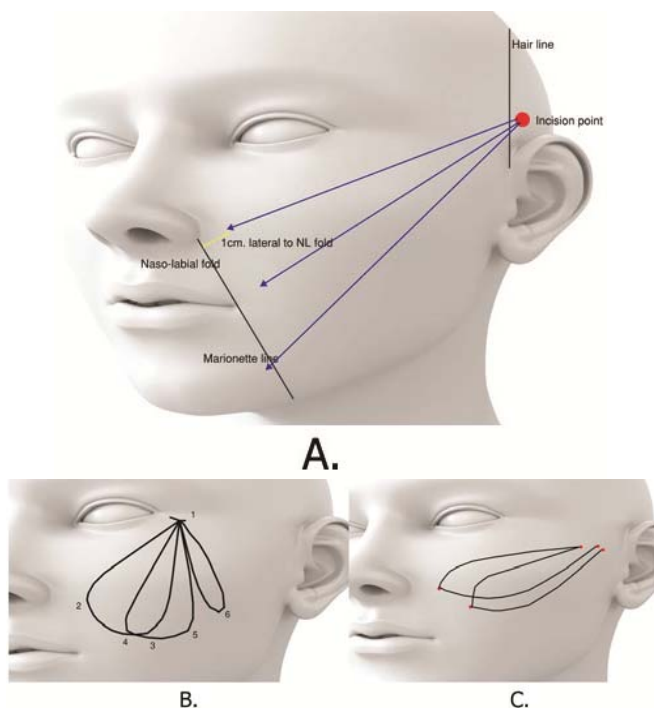


Fig. 6 Mid-face lift: (A) Uni-directional thread technique; (B) Curved needle technique; (C) Double needle technique

#### c) Eyebrow Lifting

##### *Technique 1 Straight Needle with Anchoring Point*

Make four to six incisions, 2 cm above the hairline [28]. Introduce the thread into the subgaleal plane up to the superior eyebrow margin, where it passes outside the skin and over the eyebrow via a 1 mm cutaneous incision. The eyebrow anchor is made and the thread is passed across laterally, after which it is turned upward toward the scalp area. Apply traction and make a knot, creating a rectangle (Fig. 7 (A)).

##### *Technique 2 Double Needle without Anchoring Point*

Insert both straight needles at the hairline. Follow the line within the subcutaneous tissue, advancing both needles downward until reaching the central eyebrow. Using the same exit hole, reinsert the medially positioned needle and follow the contour of the eyebrow toward the nasal edge, while the lateral needle follows the contour of the eyebrow laterally. Both needles are then advanced upward until reaching the hairline, forming a symmetrical pattern. No sutures are necessary (Fig. 7 (B)).

##### *Technique 3 Double Needle without Anchoring Point*

In a single puncture, insert both straight needles into the temple area and then trace the needles downward toward the temporal muscle. Separate the needles from each other and insert them deep into the temporal fascia before withdrawing into the subcutaneous space. Follow the line to the highest point of the brow. At this time, the needles are moved to the surface, turned around, and reinserted to trace medially in the direction of the glabella. In the middle of the upper glabella, both needles are brought out together. Pull the four sutures

ends lightly and trim the excess thread. No sutures are necessary (Fig. 7 (C)).

#### d) Neck Lifting

##### *Technique 1 Straight Needle with Anchoring Point*

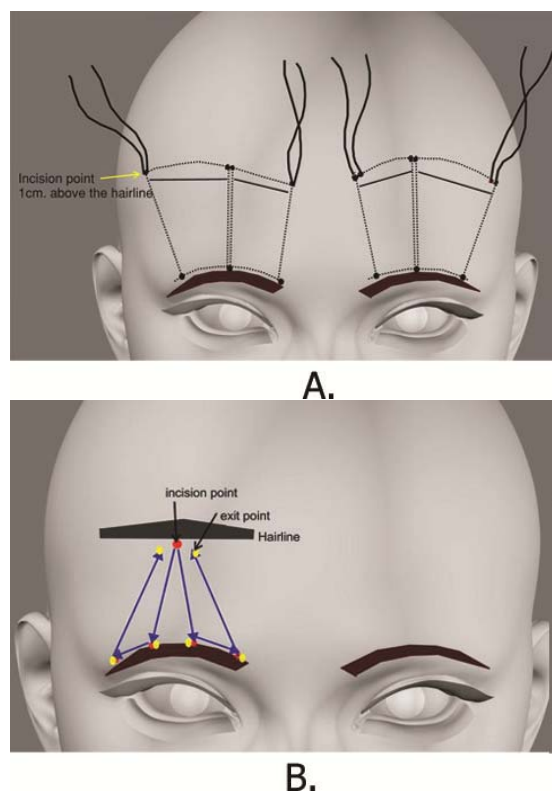
Make a 1 cm incision in the retroauricular area. Tie a knot. Trace the threads medially and exit at the midline (Fig. 8 (A)).

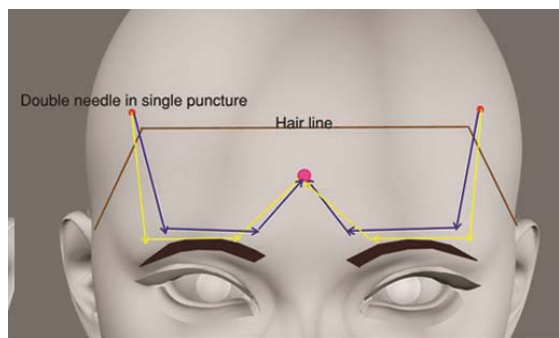
##### *Technique 2 Long Straight Needle with Anchoring Point*

Make a 1 cm incision bilaterally in the retroauricular area. At the incision area make a “Holder” thread with 2/0 Prolene and anchor it on the periosteum to support the other threads. Trace the thread along the first marked line until it appears on the other side. The needle is brought to the surface, turned around, and reinserted at the point it is brought out. Finally, trim the excess thread (Fig. 8 (B)).

##### *Technique 3 Double Needle without Anchoring Point*

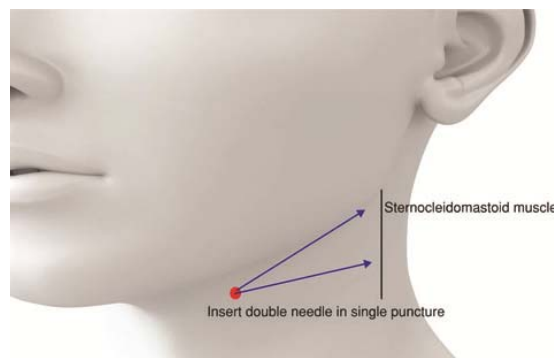
Insert both straight needles into the aponeurosis of the platysma. Follow the line to the area of the sternocleidomastoid muscle. Pull both ends of the threads lightly and then trim the excess thread. No sutures are necessary (Fig. 8 (C)).





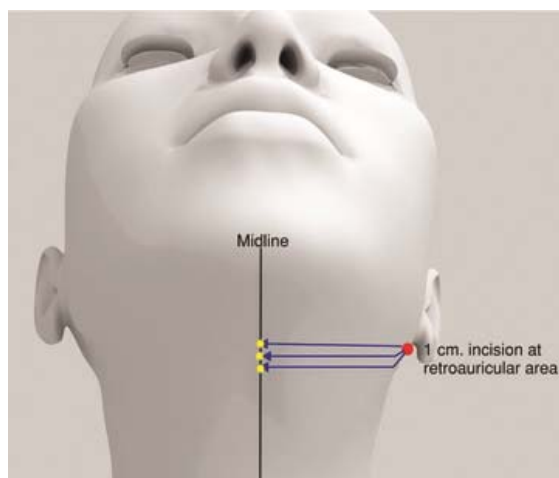
C.

Fig. 7 Eyebrow lift: (A) Uni-directional thread technique; (B) and (C) Double needle technique

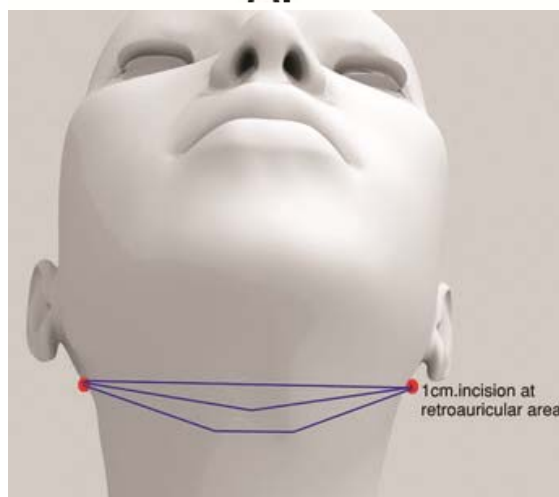


C.

Fig. 8 Neck lift: (A) and (B) Uni-directional thread technique; (C) Double needle technique



A.



B.

*E. How to Choose the Appropriate Technique for the Selected Patient*

Patients who are suitable for lifting operations have a slightly unclear mandibular margin, sagging of the zygomatic malar region, naso-buccal deepening, forehead wrinkles, eye wrinkles, lax neck skin, a double chin, or a fat pad in the neck area. Patients with advanced facial lipoatrophy, excessive laxity of the skin that requires removal, or advanced cutaneous or muscular prolapse, as well as those who request immediate results, or exaggerated lifting similar to traditional lifting, are not suitable for the thread lift procedure. To select the appropriate thread and suture technique for each patient, the physician should focus on the specific patient defect and primary area of patient concern. In accordance with this viewpoint, we suggest utilizing the patient-based algorithm shown in Fig. 9.

III. DISCUSSION

The thread lift procedure has been popularized over the past 10 years. Presently, there are several techniques that have been developed to help meet patient expectations and improve patient satisfaction, as summarized in the two protocols presented in this topic review (Short and Long suture technique protocols). The primary focus should be the area of patient concern, the physician assessment of the physical problem, and selection of the most appropriate technique for the patient (as suggested in the patient-based algorithm (Fig. 9)). Moreover, the physician should explain all the advantages, disadvantages, limitations of the selected technique, and potential complications [18], [23], [29]-[34] to the patient.

IV. CONCLUSION

According to the collected data that has been summarized in this review, several techniques of the thread lift procedure have been indicated. However, positive results depend on the process of patient selection (good candidates), as well as selection of the most appropriate technique for the patient. Based on our current knowledge of thread lifting, we hypothesize that future trends will include thread lift with growth factors that can enhance the wound healing process

and thread lift with substances that could induce lipolysis to enhance a V-shaped face.

**Patient base Algorithm**

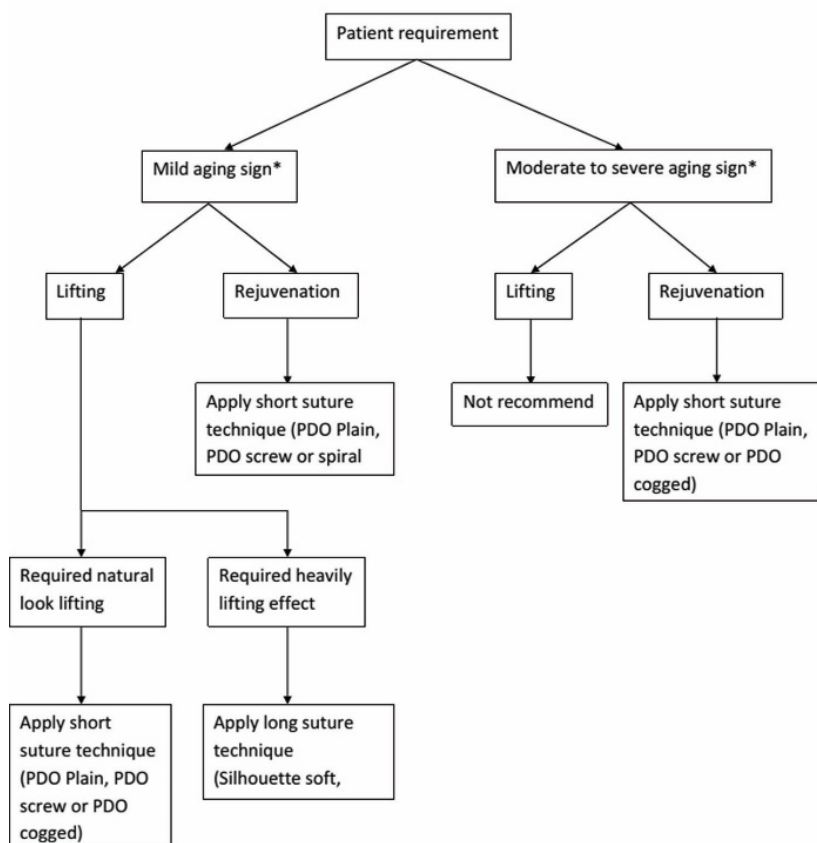

Fig. 9 Patient-based algorithm \*Mild aging signs include: slightly unclear mandibular margin, need for V-Shaped lifting, naso-buccal deepening, and relaxed neck and chin skin. \*Moderate to severe aging signs include: marked unclear mandibular margin, downward slope of the zygomatic malar region, facial lipoatrophy, severe naso-buccal deepening, and a double chin or excessive fat pad under the neck. \*Silhouette soft: We recommend that long suture technique to be applied with Silhouette soft absorbable, bidirectional thread (not required to be fixed and easy to apply) for patients who require a heavy lifting effect

REFERENCES

[1] Goldstein SA, Goldstein SM. Anatomic and aesthetic considerations in midfacial rejuvenation. *Facial Plast Surg.* 2006;22(2):105-11.

[2] De Cordier BC, de la Torre JI, Al-Hakeem MS, Rosenberg LZ, Costa-Ferreira A, Gardner PM, et al. Rejuvenation of the Midface by Elevating the Malar Fat Pad: Review of Technique, Cases, and Complications. *Plast Reconstr Surg.* 2002;110.

[3] Owsley JQ. Elevation of the malar fat pad superficial to the orbicularis oculi muscle for correction of prominent nasolabial folds. *Clin Plast Surg.* 1995;22(2):279-93.

[4] Gosain AK, Klein MH, Sudhakar PV, Prost RW. A volumetric analysis of soft-tissue changes in the aging midface using high-resolution MRI: implications for facial rejuvenation. *Plast Reconstr Surg.* 2005;115(4):1143-52.

[5] Bartholomew RS. PDS (polydioxanone suture): a new synthetic absorbable suture in cataract surgery. A preliminary study. *Ophthalmologica.* 1981;183(2):81-5.

[6] Middleton JC, Tipton AJ. Synthetic Biodegradable Polymers as Medical Devices 1998.

[7] Boland ED, Coleman BD, Barnes CP, Simpson DG, Wnek GE, Bowlin GL. Electrospinning polydioxanone for biomedical applications. *Acta Biomater.* 2005;1:115-23.

[8] Gamboa GM, Vasconez LO. Suture suspension technique for midface and neck rejuvenation. *Ann Plast Surg.* 2009;62(5):478-81.

[9] Kalra R. Use of barbed threads in facial rejuvenation. *Indian J Plast Surg.* 2008;41.

[10] DeLorenzi CL. Barbed sutures: Rationale and technique. *Aesthet Surg J.* 2006;26(2):223-9.

[11] Rashid RM, Sartori M, White LE, Villa MT, Yoo SS, Alam M. Breaking strength of barbed polypropylene sutures: rater-blinded, controlled comparison with nonbarbed sutures of various calibers. *Arch Dermatol.* 2007;143(7):869-72.

[12] Suh DH, Jang HW, Lee SJ, Lee WS, Ryu HJ. Outcomes of polydioxanone knotless thread lifting for facial rejuvenation. *Dermatol Surg.* 2015;41(6):720-5.

[13] Horne DF, Kaminer MS. Reduction of face and neck laxity with anchored, barbed polypropylene sutures (Contour Threads). *Skin Therapy Lett.* 2006;11(1):5-7.

[14] Wu WTL. Nonsurgical facelifting with long barbed suture slings: The Woffleslift. *J Aesthet Chir.* 2013;1:13-9.

[15] Shimizu Y, Terase K. Thread lift with absorbable monofilament threads. *Japan J Aesth Plast Surg.* 2013;35(2).

[16] Bacci PA. T3 - Soft Face Lift by Suspension Surgery In: Serdev N, editor. *Miniinvasive Face and Body Lifts – Closed Suture Lifts or Barbed Thread Lifts.* Croatia: Intech; 2013.

[17] Park TH, Seo SW, Whang KW. Facial rejuvenation with fine-barbed threads: the simple Miz lift. *Aesthetic Plast Surg.* 2014;38(1):69-74.



- [18] Llorca V, Soyano S. Lifting effect with polydioxanone absorbable threads without anchors on face and neck. *Approaches to Aging control* 2014;18(1).
- [19] Park TH. Facial Rejuvenation with Fine-Barbed Threads: The Simple Miz Lift. *Aesth Plast Surg.* 2014;38(1):69-74.
- [20] Mendelson BC. Anatomic Study of the Retaining Ligaments of the Face and Applications for Facial Rejuvenation. *Aesth Plast Surg.* 2013;37:513-5.
- [21] Verpaele A, Tonnard P. LowerThird of the Face: Indications and Limitations of the Minimal Access Cranial Suspension Lift. *Clin in Plast Surg.* 2008;35(4):645-59.
- [22] Sulamanidze M, Sulamanidze G, Vozdvizhenskiy I, Sulamanidze K, A. Kadzhaya. New Method of Face Elastic Thread Lift. In: Serdev N, editor. *Miniinvasive Face and Body Lifts - Closed Suture Lifts or Barbed Thread Lifts.* Croatia: Intech; 2013.
- [23] Sulamanidze M, Sulamanidze G, Vozdvizhenskiy I, Sulamanidze C. Avoiding complications with Aptos sutures. *Aesthet Surg J.* 2011;31(8):863-73.
- [24] Lee SY, Sung KY. Subcision Using a Spinal Needle Cannula and a Thread for Prominent Nasolabial Fold Correction. *Arch Plastic Surg.* 2013;40:256-8.
- [25] Graziosi AC, Beer SMC. Browlifting with Thread: The Technique Without Undermining Using Minimum Incisions. *Aesth Plast Surg.* 1998;22:120-5.
- [26] Atiyeh BS, Dibo SA, Costagliola M, Hayek SN. Barbed sutures “lunch time” lifting: evidence-based efficacy. *J Cosmet Dermatol.* 2010;9:132-41.
- [27] Paul MD. Barbed sutures for aesthetic facial plastic surgery: indications and techniques. *Clin Plast Surg.* 2008;35(3):451-61.
- [28] Ghalambor A, Pipelzadeh MH. A non-aggressive forehead/brow lift with contour threads: A case report and its application in Iran. *Pak J Med Sci.* 2006;22(3 ):320-2.
- [29] Paul MD. Complications of barbed sutures. *Aesthetic Plast Surg.* 2008;32(1):149.
- [30] Silva-Siwady JG, Diaz-Garza C, Ocampo-Candiani J. A case of Aptos thread migration and partial expulsion. *Dermatol Surg.* 2005;31(3):356-8.
- [31] Kaminer MS, Bogart M, Choi C, Wee SA. Long-term efficacy of anchored barbed sutures in the face and neck. *Dermatol Surg.* 2008;34(8):1041-7.
- [32] Sulamanidze M, Sulamanidze G. Facial lifting with Aptos Methods. *J Cutan Aesthet Surg.* 2008;1(1):7-11.
- [33] Abraham RF, Defatta RJ, William EF. Thread-lift for Facial Rejuvenation Assessment of Long-term Results *Arch Facial Plast Surg.* 2009;11(3):178-83.
- [34] Padin VL. Experience in the Use of Barbed Threads and Non-Barbed Serdev Sutures in Face and Body Lift– Comparison and Combination Miniinvasive Face and Body Lifts – Closed Suture Lifts or Barbed Thread Lifts Croatia: Intech; 2013.