

Automatic Method for Exudates and Hemorrhages Detection from Fundus Retinal Images

A. Biran, P. Sobhe Bidari, K. Raahemifar

Abstract—Diabetic Retinopathy (DR) is an eye disease that leads to blindness. The earliest signs of DR are the appearance of red and yellow lesions on the retina called hemorrhages and exudates. Early diagnosis of DR prevents from blindness; hence, many automated algorithms have been proposed to extract hemorrhages and exudates. In this paper, an automated algorithm is presented to extract hemorrhages and exudates separately from retinal fundus images using different image processing techniques including Circular Hough Transform (CHT), Contrast Limited Adaptive Histogram Equalization (CLAHE), Gabor filter and thresholding. Since Optic Disc is the same color as the exudates, it is first localized and detected. The presented method has been tested on fundus images from Structured Analysis of the Retina (STARE) and Digital Retinal Images for Vessel Extraction (DRIVE) databases by using MATLAB codes. The results show that this method is perfectly capable of detecting hard exudates and the highly probable soft exudates. It is also capable of detecting the hemorrhages and distinguishing them from blood vessels.

Keywords—Diabetic retinopathy, fundus, CHT, exudates, hemorrhages.

I. INTRODUCTION

DR is a vascular disease of the retina. DR starts when diabetes mellitus damages small retinal blood vessels. As the damage increases, it causes formation of hemorrhages deep inside the retina. As the disease advances, the retina reacts by growing abnormal blood vessels which are weak, leaky, fragile, and misdirected. The more these abnormal blood vessels grow, the more they bleed and pull on the retina. In addition, the leaked fluid produces sediments composed of lipid byproducts called exudates. Exudates are yellow and appear in different sizes and locations within the retina. Exudates fall into two main categories of hard and soft exudates. The former ones are brighter. In fact, patients do not suffer from any vision problems until later stages of the disease when treatments may not be effective anymore. Therefore, it is very important that patients with diabetes undergo an annual eye exam because early diagnose of this disease is very important in preventing blindness.

Several algorithms have been proposed to detect exudates. Reza et al. [1] presented an algorithm to detect exudates using an image processing technique based on average filtering, contrast adjustment, morphological opening, and watershed transformation [1]. Tripathi et al. [2] proposed a new method for automatic extraction of exudates based on differential morphological profile (DMP). The first stage in their proposed algorithm was Gaussian smoothing on the green channel of the

input, followed by contrast enhancement. The DMP was used to detect bright regions which are mainly exudates. Mansour et al. [3] presented a three-stage algorithm based on Discrete Cosine Transform for feature extraction, color histogram equalization for exudate detection and Support Vector Machine for classification. Akter et al. [4] proposed an improved method for exudates extraction based on nonlinear background elimination. On the other hand, Kleawsirikul et al. [5] presented an automated algorithm based on morphological Top Hat for extracting hemorrhages. The extracted hemorrhages were classified by using rule based classification. In the other research papers, different methods of hemorrhage detection have been proposed by using mathematical morphology [6], splat feature classification [7] and support vector machine classifier [8]. Moreover, Acharya et al. have been used a morphological image processing methodology to detect different lesions inside the eye [9]. In their study, Ball-shaped structuring elements were used along with morphological operators to extract an image including only the blood vessels. By increasing the structuring element size, an image with both blood vessels and hemorrhage was extracted. Then, the hemorrhages were detected by subtracting the two images. Fig. 1 shows the hemorrhages, exudates, Optic Disc (OD) and blood vessels.

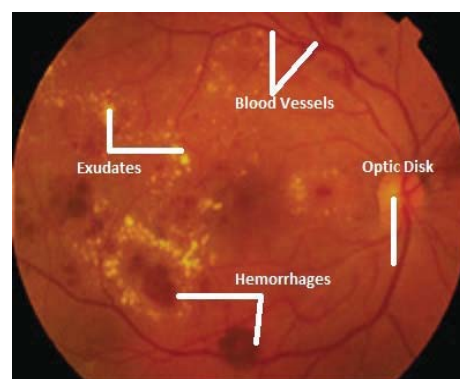


Fig. 1 Fundus images with lesions

The OD and exudates appear yellow in fundus images. Therefore, many algorithms have localized and deleted OD in order to better detect exudates. Amin et al. [10] proposed an OD removal algorithm based on histogram matching. First, they extracted the histogram of color component using the OD of some images from DRIVE database. Then, the average histograms of each color were calculated, followed by localizing

Abdullah Biran is with the Ryerson University, Canada (e-mail: Bmebiran@gmail.com).

the center of the OD. Foracchia et al. [11] also proposed a new method for OD localization. Their technique was based on detecting the main vessels as they originate from the OD in a similar directional pattern. Then they proposed a geometrical parametric model to describe any retinal vessel direction, and the OD was determined by using two model parameters. Some other studies have used different methods such as Hough transform [12] and impact active counters [13] to locate the OD.

II. PROPOSED METHODOLOGY

In this paper, we present an automatic improved algorithm for hemorrhage and exudate detection. The algorithm is based on several image processing techniques. The first stage is to extract the green channel component of the color fundus image, followed by detection of the eye and the OD using CHT. Then, the CLAHE is used to enhance the image. The hemorrhages and exudates are detected separately. Exudates are extracted by using a combination of CLAHE image and two dimensional Gabor filter image followed by a thresholding technique. Hemorrhages are detected by combining thresholding and CHT algorithms. The flowchart of the proposed method is shown in Fig. 2. In the following, the proposed algorithm is explained.

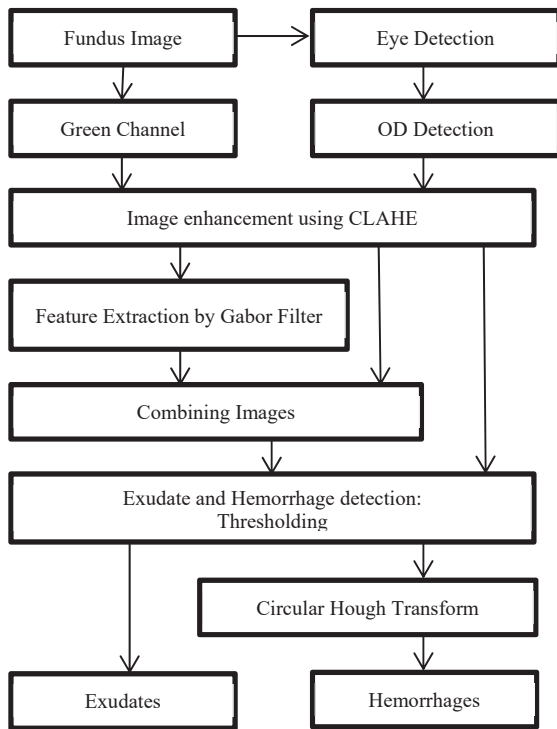


Fig. 2 The flowchart of the proposed algorithm for detecting exudates and hemorrhages

A. Fundus Images and Green Channel

Fundus images contain information about the internal structures of the human eye including the retina, OD, macula, fovea, and blood vessels. In this project, images from STARE and DRIVE databases were used. The green channel of the RGB fundus images was used in the proposed method since it provides the best vessel/background contrast.

B. Eye Detection

The CHT is a feature extraction method for detecting the circular shapes in an image. This technique is a special form of Hough Transform. Therefore, the eye as the largest bright circle in the fundus image is detected by CHT. This allows eliminating the background and its destructive effects on the proposed detection method.

C. OD Detection

In fundus images, the OD and exudates are very similar in color but different in shape and size. Therefore, the OD is detected in this stage using CHT by finding the largest bright circle in a specified region inside the eye.

D. Image Enhancement

The CLAHE algorithm enhances the contrast among the small regions of an image known as tiles. The contrast of each tile is individually enhanced to obtain a uniform histogram. Then the resulted enhanced images over tiles are combined by interpolation. In this stage of the proposed method, a new improved image is extracted by combining the green channel image and the OD eliminated image using CLAHE. Then, the exudates and hemorrhages are extracted separately.

E. Gabor Filter

The two dimensional Gabor filter is a well-known feature extraction algorithm based on Continuous Wavelet Transform (CWT). Gabor filter was used in the proposed algorithm to extract blood vessels and exudates from CLAHE image. After that, a new and improved image was extracted by combining both the CLAHE and Gabor filter images. Gabor is defined as:

$$\sigma_x = \sigma \quad (1)$$

$$\sigma_y = \frac{\sigma_x}{\gamma} \quad (2)$$

$$g(x, y) = \exp\left(-0.5\left(\frac{x_\theta^2}{\sigma_x^2} + \frac{y_\theta^2}{\sigma_y^2}\right)\right) \cos\left(\frac{2\pi x_\theta}{\lambda} + \phi\right) \quad (3)$$

$$x_\theta = x \cos(\theta) + y \sin(\theta) \quad (4)$$

$$y_\theta = -x \sin(\theta) + y \cos(\theta) \quad (5)$$

where σ_x and σ_y are the standard deviations of Gaussian in x and y direction along the filter, θ is the orientation of the filter, λ is the wavelength of the cosine factor of the Gabor filter, and ϕ is the phase offset.

F. Thresholding

Thresholding is the process of segmenting image pixels into two or more classes based on their intensity by applying an optimized threshold (T). The exudates are the brightest parts of the image; thus, an optimized threshold was obtained to extract them from the Gabor and CLAHE combined image. The results show hard exudates and soft exudates separately. On the other hand, since hemorrhages and blood vessels are very similar in intensity, an optimized threshold was determined to extract them from the CLAHE image. Hemorrhages differ from blood vessels

in shape; they usually appear in circular or semicircular shapes. Therefore, CHT is used to differentiate hemorrhages from blood vessels.

III. RESULTS

Figs. 3 and 4 show the results of the detection process for hemorrhages and exudates, respectively. In Fig. 3, the process of extracting hemorrhages using an image from DRIVE database is shown. First, the green channel is extracted and the OD is localized. Then, the image is enhanced and the hemorrhages are detected.




Fig. 3 The process of extracting hemorrhages: (a) RGB image, (b) Green channel component, (c) OD detection, (d) OD elimination, (e) Image enhancement using CLAHE, (f) Hemorrhages detection

In Fig. 4, the process of extracting exudates using an image from STARE database is shown. First, the green channel is extracted and the OD is localized. Then, the image is enhanced and the main features are extracted. Finally, the hard exudates are detected separately.




Fig. 4 The process of extracting Exudates: (a) RGB image, (b) Green channel component, (c) OD detection, (d) OD elimination, (e) image enhancement using CLAHE, (f) Gabor filter image, (g) Combined image, (h) All exudates detection, (i) Hard Exudates

IV. DISCUSSION

Extracting hemorrhages and exudates is an essential process for detecting DR which is the main cause of blindness. In this project, an automatic algorithm has been proposed to extract either exudates or hemorrhages from RGB fundus images from DRIVE and STARE databases. The proposed algorithm accurately detects hard exudates, soft exudates and hemorrhages

using different image processing techniques including CHT, CLAHE, Gabor filter, and thresholding.

In future works, the presented algorithm can be used for advanced retinal image processing for the purpose of classifying different types of DR based on detecting its signs.

REFERENCES

- [1] A. W. Reza, C. Eswaran and S. Hari, "Automatic Tracing of Optic Disc and Exudates from color Fundus Images Using Fixed and Variables Thresholds," *Journal of Medical Systems*, Vol. 33, pp. 73-80, April. 2008.
- [2] A. Tripathi, K. K. Singh, B. K. Singh and A. Mehrotra, "Automatic Detection of Exudates in Retinal Fundus Images using Morphological Profile," *International Journal of Engineering and Technology*, Vol. 3, pp. 2024-2029, July 2013.
- [3] R. F. Mansour, E. Md. Abdelrahim and A. S. Al-Johani, "Identification of Diabetic Retinal Exudates in Digital Color Images Using Support Vector Machine," *Journal of Intelligent Learning Systems and Applications*, pp. 134-142, August 2013.
- [4] M. Akter, A. Rahman and A.K.M. Islam, "An improved method of automatic exudates detection in retinal images," *International Journal Innovative Research in Electrical, Electronics, Instrumentation and Control Engineering*, Vol. 2, May 2014.
- [5] N. Kleawsirikul, S. Gulati and B. Uyyanonvara, "Automated Retinal Hemorrhage Detection using Morphological Top Hat and Rule-based Classification," *3rd International Conference on Intelligent Computational Systems*, April 2013.
- [6] S. B. Junior and D. Walfer, "Automatic Detection of Microaneurysms and Hemorrhages in Color Eye Fundus Images," *International Journal of Computer Science and Information Technology*, Vol. 5, October 2013.
- [7] R. V. Athira and D. F. Ferlin, "Detection of Retinal Hemorrhage using Splat Feature Classification Technique," *International Journal of Engineering Research and Applications*, Vol. 4, pp. 327-330, January 2014.
- [8] R. Inbarathi and R. Karthikeyan, "Detection of Retinal Hemorrhage in Fundus Images by classifying the Splat Features using SVM," *International Journal of Innovative research in Science, Engineering and Technology*, Vol. 3, pp. 1979-1986, March 2014.
- [9] UR Acharya, CM. Lim, EYK. Ng and T. Tamuraa, "Computer-Based Detection of diabetes retinopathy stages using digital fundus images," pp. 545-553, July 2009.
- [10] A. Dehghani, H.A. Moghaddam and M.S. Moin, "Optic disc localization in retinal images using Histogram matching," *EURASIP on image and Video Processing*, December 2012.
- [11] P. C. Siddalingeswamy and K. G. Prabhu, "Automatic Localization and Boundary Detection of Optic Disc Using Implicit Active counters," *International Journal of Computer Applications*, Vol. 1, February 2010.
- [12] M. Foracchia, E. Grisan and A. Ruggeri, "Detection of Optic Disc in Retinal Images by Means of a Geometrical Model of Vessel Structure," *IEEE Transactions on Medical Imaging*, Vol. 23, pp. 1189-1195, October 2014.
- [13] S. Sekhar, W. AL-Nuaimy and K. Nandi, "Automated Localization of Optic Disc and Fovea in Retinal Fundus Images," *16th European Signal Processing Conference*, August 2008.