

Computer-Aided Classification of Liver Lesions Using Contrasting Features Difference

Hussein Alahmer, Amr Ahmed

Abstract—Liver cancer is one of the common diseases that cause the death. Early detection is important to diagnose and reduce the incidence of death. Improvements in medical imaging and image processing techniques have significantly enhanced interpretation of medical images. Computer-Aided Diagnosis (CAD) systems based on these techniques play a vital role in the early detection of liver disease and hence reduce liver cancer death rate.

This paper presents an automated CAD system consists of three stages; firstly, automatic liver segmentation and lesion's detection. Secondly, extracting features. Finally, classifying liver lesions into benign and malignant by using the novel contrasting feature-difference approach. Several types of intensity, texture features are extracted from both; the lesion area and its surrounding normal liver tissue. The difference between the features of both areas is then used as the new lesion descriptors. Machine learning classifiers are then trained on the new descriptors to automatically classify liver lesions into benign or malignant. The experimental results show promising improvements. Moreover, the proposed approach can overcome the problems of varying ranges of intensity and textures between patients, demographics, and imaging devices and settings.

Keywords—CAD system, difference of feature, Fuzzy c means, Liver segmentation.

I. INTRODUCTION

LIVER is an important organ that perform vital functions such as detoxification of hormones, drugs, filter the blood from waste products, production of proteins required for blood clotting.. However, diseases can occur without warning and early detection will help to reduce the cancer death and becomes critical to successful treatment. Global Cancer Statistics [1] reported that, worldwide, liver cancer was the fifth most commonly diagnosed and the second-leading cause of cancer death for the men. While in women, it is the seventh most frequently diagnosed and the sixth most common cause cancer death. Moreover, incidence statistic's rate of liver cancer was increasing across many parts of the world where most patients who are diagnosed with liver cancer die within six months of diagnosis.

There are various imaging modalities such as Computed tomography (CT) scan, Ultrasound, X-Ray, and Magnetic Resonance Imaging (MRI) used to diagnose liver lesions. The CT scan is often preferred for diagnosing liver diseases, especially as being considered of high accurate imaging and cheaper than MRI [2], [3]. However, liver segmentation and liver lesion detection can be a very challenging task and it depends on the experience of the radiologist and that's referring

to small noticeable changes between healthy liver tissue and lesion [4]. Generally, along with the improvements in image processing and artificial intelligence designing and developing systems for computer-aided diagnosis (CAD) to characterise liver lesions have received considerable attention over the past years. These systems can provide diagnostic assistance to clinicians for the improvement of diagnosis and increasing the accuracy [5]. This contributes towards avoiding the risk of liver biopsy and surgery.

A general automatic/semi-automatic CAD system is supposed to provide complete assistance to doctors in diagnosis of liver cancer. Additionally, it consists of three stages: liver segmentation and lesion detection, features extraction, and classification of liver diseases by means of a classifier [2].

Feature extraction is very important phase in CAD system, to use in classification of lesion. Low level features [6], [7] are usually applied for understanding radiological images by provides certain parameters, on the basis of which classification system takes decision. After the lesion detection is performed on segmented liver, the features can be obtained from it and fed the machine learning to classify lesion. The entire features which are extracted from the image convey some information regarding liver lesion. This information is very helpful in classifying lesion as Benign or Malignant. Therefore, several approaches have been proposed to extract appropriate features to use with classifier for diagnose liver diseases.

In this paper, the overview of various liver diseases' classification methodologies depends on intensity, texture features and combination between intensity and texture features is explained briefly. The novelty of this work is using difference of intensity and texture features between lesion and surrounding area from normal liver tissue to classify liver lesion into benign or malignant.

The paper is organised as follows. Section II presents the related research from the body of literature. Section III presents the proposed work, which includes Liver segmentation and lesion detection, feature extraction, and classification. Section IV deals with experiments results and discussion while Section V summarizes the study findings through the conclusion.

II. RELATED WORK

Several CAD systems have been developed to classify liver lesions into benign (noncancerous) and malignant (cancerous). The most common examples of benign lesions are Cyst, Hemangioma, Hepatic adenoma, and Focal nodular.

H. A. and A. A. are with the Computer Science Department, University of Lincoln, Lincoln, United Kingdom (e-mail: halahmer@lincoln.ac.uk, aahmed@lincoln.ac.uk).

The main core in a CAD system is the features extraction stage. Hence, previous research on CAD systems can be categorised based on the type of features, into intensity-based features, texture-based features or combined features that include any combination of intensity and texture features were used in segmentation and as an input data for classifier. While shape features gained more attention in liver segmentation and lesions characterisation.

Among the various liver segmentation, lesion detection and feature extraction techniques, [8] proposed automatic liver lesion detection method from CT images without segmenting liver by determined the intensity of the liver and lesion pixels in the range of [-50, 250] Hounsfield Units (HU) for each CT slice, only those pixels are incorporated, which are located in the right side of the body and the intensity of which is in the range [-50, 250] HU (air, fat, and bones are excluded). Thus, the largest connected region is considered as the region of interest (ROI). The developed method employs an over-segmentation algorithm called 'Simple Linear Iterative Clustering (SLIC)' to generate high-quality and nearly uniform superpixels (small region) in ROIs of liver CT slice and adapt the Naive Bayes Nearest Neighbour (NBNN) classifier to score the superpixels and classify hyperdense, hypodense, and heterogeneous liver lesions. Where this method tested on 442 CT slices of 129 patient and lesions are manually outlined. The pixel-wise accuracy for detection and classification can achieve 93.4%. An important advantage of nonparametric method when compared to other methods, that required training for detection liver lesions and classification is direct utilisation of lesion features, which makes it flexible and easy to implement. On the other hands, image dataset and the local descriptors consider the main role in the detection performance and just depend on single-phase CT slices to detect lesion.

Classification of a lesion on the basis of intensity like gray level information or shape is not easy due to shape of each lesion is not consistent in all slices of CT images, in additional to overlap gray level noticeably for soft tissue. Therefore, texture features gained more attention to distinguish different lesions. Several researchers have been proposed several approaches based on texture features with various classifiers for liver tumors classification.

Mala et al. [9] developed an automatic system for liver segmentation and classification lesions into the benign and malignant tumor by using biorthogonal wavelet transform with Linear Vector Quantization (LVQ) neural network classifier. The LVQ neural network is trained using the obtained features. The system is tested with 100 images consists of malignant (34 HCC, 18 cholangio carcinoma cases) and benign (30 hemangioma and 18 adenoma cases). The classification performance obtained is 92%. However, Work has been extended to categorise liver disease to fatty or cirrhosis. Firstly, this used the orthogonal wavelet transform on the liver to compute horizontal, vertical and diagonal information. Secondly, statistical texture features such as mean, standard deviation, contrast, entropy, homogeneity and angular second moment are extracted from this information. Finally, Probabilistic Neural Network (PNN) is used for classification

the liver lesion. The proposed system used 100 images obtained from 50 fatty and 50 cirrhosis for tested and it recorded an accuracy rate of 95%. [10] Another automatic classification system from CT scan images was proposed by [11]. The proposed system was used various types of texture features (biorthogonal wavelet, GLCM and FDCT) to train different type of neural networks (NN), namely: Propagation Network (BPN), PNN, and Cascade feed forward BPN (CFBPN). Totally number of images is 70, which used for training and testing which divided into 40 hepatoma (malignant) and 30 hemangioma (benign). The combinations feature for kurtosis, skewness, energy, information correlation, inverse difference moment; entropy showed better performance in BPN, PNN, and CFBPN neural networks with obtained 96% accuracy. Gray scale co-occurrence matrix is extracted from tumor image and all extracted features are used as input to every NN. However, BPN classifier is performed well with accuracy obtained 96%. While the accuracy results of PNN and CFBPN less when compared with BPN to record 95.83% and 91% respectively when. On the other hand, the accuracy results are equalled for BPN, PPN and CFBPN to record 96% when used FDCT to extract the features from tumor image and used as input to every NN. Although the training and testing dataset is small but the result of the segmentation algorithm proved the effectiveness. In yet another fully automated classification system was presented by [12]. The proposed CAD system was able to classifying a liver lesion into hepatocellular (malignant) or hemanogioma (benign) by extracting gray level texture (GLT), wavelet coefficient statistics and contourlet coefficient statistics from lesions combined with probabilistic neural network classifier to differentiating malignant from a benign lesion. Dataset used in proposed CAD system totally 300 images divided into 150 benign and other 150 malignant to recorded accuracy 96.7%. Where other approaches have been proposed to address the liver lesion classification based on combination intensity features with a texture feature. Doron et al. [13] proposed CAD system which automatically classifies liver lesions marked by expert from CT images to Benign and Malignant by using several types of texture features and intensity features extracted from a given lesions area as a region of interest. Gray Level Co-occurrence Matrix (GLCM), Local Binary Patterns (LBP), Gabor, gray level intensity values and Gabor-based LBP (GLBP) where the dataset includes 25 cases malignant and 67 cases benign. SVM and KNN classifiers were used as a classification module which results of accuracy recorded 91% when using Gabor filtering with SVM. However, the accuracy was improved with a feature vector containing three features, namely: Gabor, LBP and Gray level intensity features to reach 97% (using SVM).

Table I depicts a generic comparison between various proposed CAD systems as previously stated.

After surveying the published papers [8]-[12], it is observed that many researchers try to diagnose liver disease using different techniques to increase the classification performance. However, it has been found that the previous studies on CAD systems usually used the absolute value of features, which are extracted from lesion regions. As a consequence, the

performance is varied significantly under different acquisition conditions. For example, the CT machines or operators are different. In this study, the surrounding normal tissue of liver in the same image is used as reference. So for a certain feature, we calculate the difference of features between the lesion and surrounding normal liver tissue and employ it as a new feature vector in our proposed system.

In the current work, we focus on extracting intensity features and texture features: Histogram, Mean, Variance, Skewness, Smoothness, Kurtosis, Energy, Entropy, HaarWavelet, Tamura features, Gabor Energy. The objective of our work is to differentiate benign from malignant liver lesion.

TABLE I
 OVERVIEW OF DISCUSSED CAD SYSTEM

Authors	Year	Dataset size	Accuracy
Mala et al. [9]	2006	100	92%
Mala et al. [10]	2010	100	95%
Gunasundari et al. [11]	2012	70	96%
Wei et al. [8]	2013	129	93.4%
Kumar et al. [12]	2013	300	96.7%
Doron et al. [13]	2014	92	97%

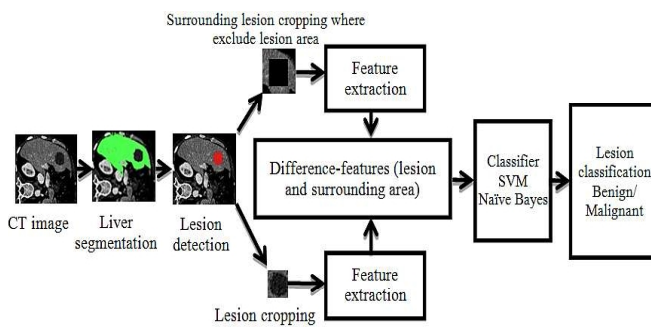


Fig. 1 CAD system architecture

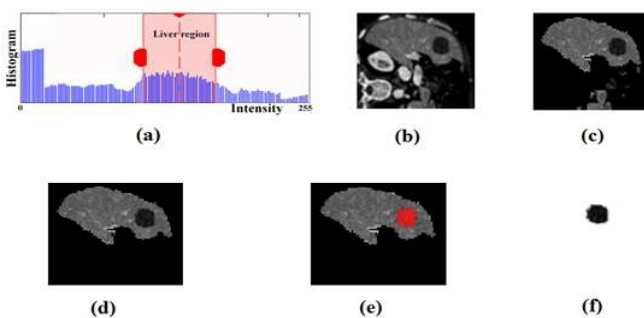


Fig. 2 Liver and Lesion segmentation process: (a) Histogram for CT; (B) Original CT image; (C) Extracted liver with noise; (d) After morphological operation; (e) Detected lesion; (f) Segmented lesion

III. PROPOSED WORK

The main goal of our CAD system is to classify CT liver lesion into one of the two classes: Benign or Malignant as presented in Fig. 1.

Firstly, the liver is segmented and the lesion is detected automatically. Secondly, Regions of Interest (ROIs) that reflect lesion on CT images and surrounding area from normal liver tissue are extracted. Three different texture feature sets are

obtained using HarrWavelet, Tamura (Coarseness, Contrast, and Directionality) and GaborEnergy, and seven intensity features are calculated through Histogram, Mean, Variance, Skewness, Kurtosis, Energy, and Smoothness. Finally, the difference of features values from lesion and normal liver tissue are combined and fed into machine learning classifier.

A. CAD System

The proposed CAD system consists of three main stages carried out in succession: (I) liver and lesion segmentation, where proposed system defined the lesion as first ROI and normal liver tissue surrounding the lesion as second ROI (II) features extraction stage; to extract intensity and texture features from lesion and surrounding area to find the difference between them, and (III) lesion classification, to classify lesion into Benign and Malignant. Fig. 1 shows an illustration of the proposed CAD system architecture.

B. Liver and Lesion Segmentation

The system uses a two-step process. Firstly, segment the liver by generating the binary liver mask. The CT grayscale image is split into three classes using a memory efficient implementation of the fuzzy c-means (FCM) clustering algorithm [14], [15]. The computational efficiency is achieved by using the histogram of the image intensities during the clustering process instead of the raw image data. After that the combinations of several morphological operations were applied to remove the smallest object outside the liver region. This is defined as (1):

$$f * b = (f \bullet b) \circ b \quad (1)$$

where f is the target image, b is the structuring element, \bullet means morphological closing, and \circ means morphological opening. Then region growing is applied to segment tumors [16], where the region is iteratively grown by comparing all unallocated neighbouring pixels to the region. The difference between a pixel's intensity value and the region's mean is used as a measure of similarity. The pixel with the smallest difference measured this way is allocated to the respective region. This process stops when the intensity difference between region mean and new pixel become larger than a certain threshold (t). The process of liver and lesion segmentation from CT image is presented in Fig. 2.

After extracting the liver and defined the lesion, the proposed system will be cropped the lesion and normal liver tissue that surrounding lesion where excluded the lesion area to extract the features from both ROI.

C. Feature Extraction

The next stage in our proposed system is feature extraction, which is considered a critical step in the CAD system to classify/characterise the lesion. Basically there is a large diverse set of features to be used. Those come under three categories; intensity, shape, and texture feature.

First of all, the proposed system defines two types of ROI for extracting the features relating to intensity and texture. The first ROI is the lesion, and the second ROI is the surrounding normal liver tissue as shown in Fig. 3.

In contrast with current trends about identification of lesions using one ROI (lesion area only), we proposed to use a second ROI which surrounds the first ROI. Moreover, the second ROI will be used as well to extract features. The difference of features between the first ROI and the second ROI will be employed as a new feature vector. However, there are some constraints to identify the second ROI: (1) The second ROI must be centrally surrounding the first ROI. (2) The ratio between the first and second ROIs are 1:1.5. (3) The first ROI is excluded from the second ROI region. As displayed in Fig. 3 (d).

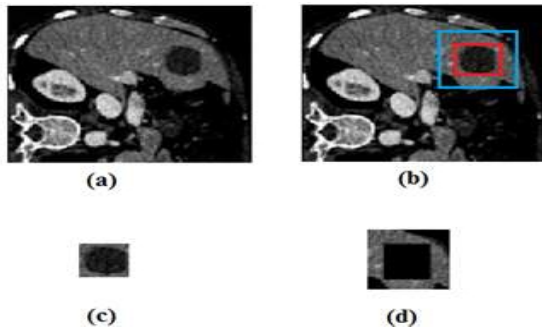


Fig. 3 Lesion and normal liver tissue segmentation: (a) Original CT image; (b) First ROI is red box for lesion and second ROI is blue box for surrounding normal liver tissue; (c) cropped lesion box; (d) cropped surrounding normal liver tissue box

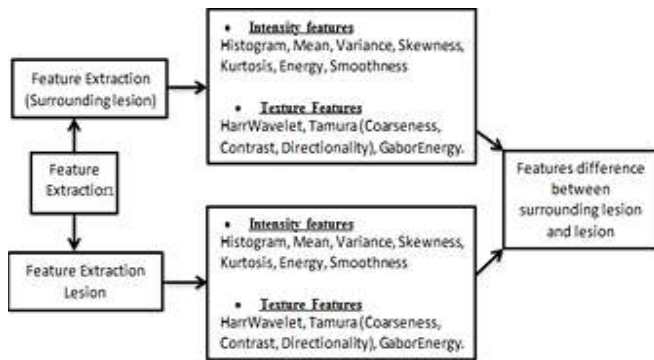


Fig. 4 Features extraction process

The most prominent features (intensity features and texture features) that represent various sets of features depend on their pixel intensity relationship and statistics will be calculated for each ROI (the lesion and surrounding area from normal liver tissue) were used the difference between them in classifier as explained in Fig. 4.

Intensity features derived from histogram features which describe the relative frequency of pixel intensity value in the image which consider Mean, Standard Deviation, Skewness, Kurtosis [19]-[21].

The mean (μ) calculate the estimation of the average level of intensity in the ROI region

$$\mu = \frac{1}{N} \sum_{(x,y) \in ROI} I(x,y) \quad (2)$$

Where $I(x,y)$ is the gray level at pixel (x,y) , and I is the total number of pixel inside the ROI. The difference of mean gray

level between the lesion and surrounding normal liver tissue is:

$$\text{difference } (\mu) = \frac{1}{N} \sum_{(x,y) \in ROI} I_{Normal}(x,y) - \frac{1}{N} \sum_{(x,y) \in ROI} I_{Lesion}(x,y) \quad (3)$$

where $I_{Normal}(x,y)$ means the gray level at pixel (x,y) of normal surrounding liver tissue ROI, $I_{Lesion}(x,y)$ means the gray level at pixel (x,y) of lesion ROI, and N is the total number of pixels inside the ROI.

Standard deviation (σ) is a measure of the dispersion of intensity

$$\sigma = \sqrt{\sum_{h=0}^{L-1} (h - \bar{h})^2 P(h)} \quad (4)$$

Skewness (γ_1) is a measure of histogram symmetry.

$$\gamma_1 = \frac{1}{\sigma^3} \sum_{h=0}^{L-1} (h - \bar{h})^3 * P(h) \quad (5)$$

Kurtosis (K) is a measure of the tail of the histogram.

$$K = \frac{\sum_{h=0}^{L-1} (h - \bar{h})^4}{(L-1)\sigma^4} \quad (6)$$

Where the difference of Standard deviation, Skewness, and kurtosis between normal liver tissue and lesion is calculated in the same way as mentioned previously in the mean calculation. As well as, three types of texture features (HaarWavelet, Gabor energy, and GLCM (Energy, Entropy, Contrast, Homogeneity, and Correlation)) were extracted for each ROI. The difference features were used to replace the lesion features value.

D. Classification

Classification is the last stage in an automated CAD system, where its input is the extracted set of feature vectors(s) from the previous stage. The goal of the classification stage is to apply a learning-based approach considering its input feature vector(s), for the purpose of disease diagnosis.

After extraction the feature from liver lesion and normal liver tissues that surrounding the lesion then will find the difference between of them to use as input to the classifier were used Support Vector Machine (SVM) and Naïve Bayes (NB). The classifier output compared with original class attribute to generate confusion matrix and identifying True Positive (TP) where malignant lesion classified as a malignant correctly, True Negative (TN) benign lesion classified as benign correctly, False Positive (FP) classified benign lesion incorrectly as malignant, and False Negative (FN) classified malignant lesion incorrectly as benign.

IV. EXPERIMENTAL RESULTS

This section contains two experiments for classification. The first one based on features extraction from a lesion to use in classifier. The second experiment focuses on extracting the features from both lesion and normal liver tissue that surround the lesion then apply the difference technique between lesion features and surrounding normal liver tissue features to generate new features vector. The new features vector will be

used in classifier to differentiate between benign and malignant liver lesion, as depicted in Fig. 5.

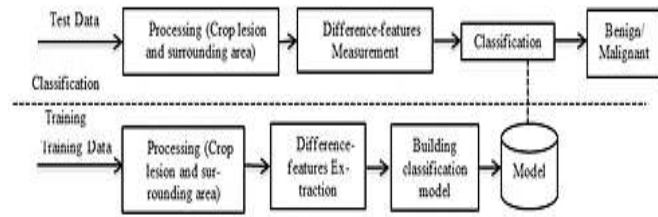


Fig. 5 Model of experiment

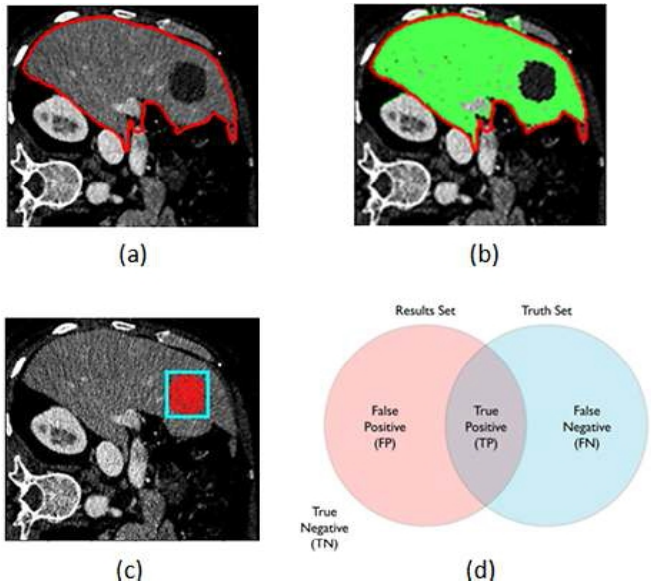


Fig. 6 Evaluation of Liver segmentation: (a) Ground truth of Liver segmentation by radiologist; (b) Overlap liver segmentation proposed system and ground truth; (c) Box is ground truth of the lesion drawn by expert and red area is the mask generated by proposed system ; (d) Set matching indicated are the true negative, false positive, false negative, and true positive areas

A. Dataset and Experimental Setup

We obtained 60 patient cases, where liver lesions are identified in CT scan and divided into malignant (33 cases) and benign (27 cases). The CT images had varied resolutions (x: 190-308 pixels, y: 213-387 pixels, slices: 41-588) and spacings (x, y: 0.674-1.007mm, slice: 0.399-2.5mm).

The experiments have been done on Intel Core I5- 3.40 GHz computer with 8 Gigabytes of RAM under windows 7 64-bit operating system. The Matlab R2014a was used to run experiments and extract the features and Weka 3.6.11 machine learning tool [22] was used for classification.

B. Evaluation and Result

This section will be displayed the evaluation and result for each segmentation stage and classification lesion in our proposed system.

• Segmentation Phase

The proposed system was tested on whole dataset. To measure the segmentation performance in all cases the two

coefficients are used to obtain the accuracy of the liver segmentation, namely: Jaccard similarity metric (JC), also known as the Tanimoto coefficient [17], and Dice coefficient [18].

As shown in Fig. 6, we define X as a set of all pixels in the image. The ground truth $T \in X$ as the set of pixels that were labelled as liver by the radiologist. Similarly, we define $S \in X$ as the set of pixels that were labelled as liver by the proposed system.

True positive set is defined as $TP = T \cap S$, the set of pixels common to T and S . True negative is define as $TN = \bar{T} \cap \bar{S}$, the set of pixels that were labelled as non-liver in both sets. Similarly, false positive set is $FP = \bar{T} \cap S$ and the false negative set is $FN = T \cap \bar{S}$.

Jaccard similarity metric,

$$J(T, S) = \frac{|T \cap S|}{|T \cup S|} = \frac{|TP|}{|TP| + |FP| + |FN|} \quad (7)$$

Dice coefficient,

$$D(T, S) = \frac{2 * |T \cap S|}{|T| + |S|} = \frac{2 * |TP|}{|TP| + |FN| + |TP| + |FP|} \quad (8)$$

The evaluate accuracy of the proposed liver segmentation method compared to the ground truth; we utilised Jaccard and Dice coefficient method which depicted in (7) and (8). The accuracy of segmentation was 0.82 and 0.9 respectively.

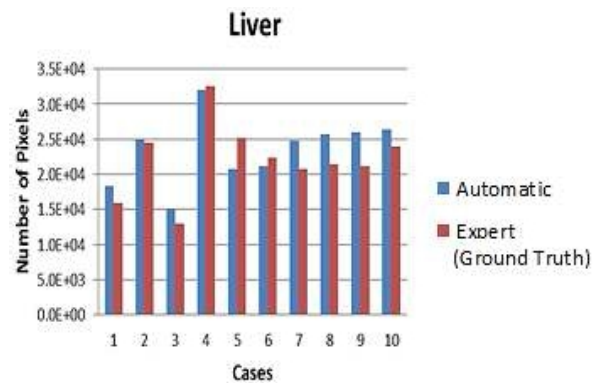


Fig. 7 Distribution of the number of segmented liver pixels

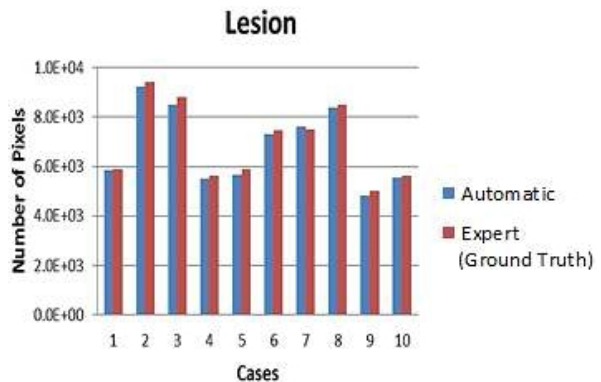


Fig. 8 Distribution of the number of segmented lesion pixels

Figs. 7 and 8 depict the performance of automatic versus

manual segmentation, in terms of the number of liver and lesion pixels for random 10 cases, where the ground truth is the manual segmentation by expert radiologist and automatic is the proposed system.

TABLE II
 RESULT OF TWO EXPERIMENTS WITH AND WITHOUT DIFFERENCE TECHNIQUE

	from lesion		difference (proposed method)	
	M	B	M	B
ACC	93.3%	93.3%	98.3%	98.3%
SE	90.9%	96.3%	97%	100%
SP	96.3%	90.9%	100%	97%
PPV	96.8%	89.7%	100%	96.4%
NPV	89.7%	96.8%	96.4%	100%

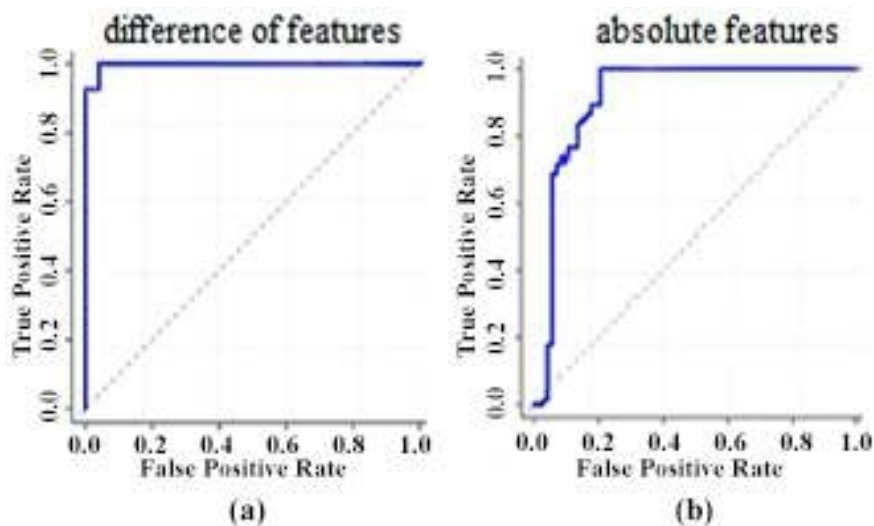


Fig. 9 ROC curves of accuracy for the classification. (a) ROC curve with using difference technique; (b) ROC curve with absolute feature

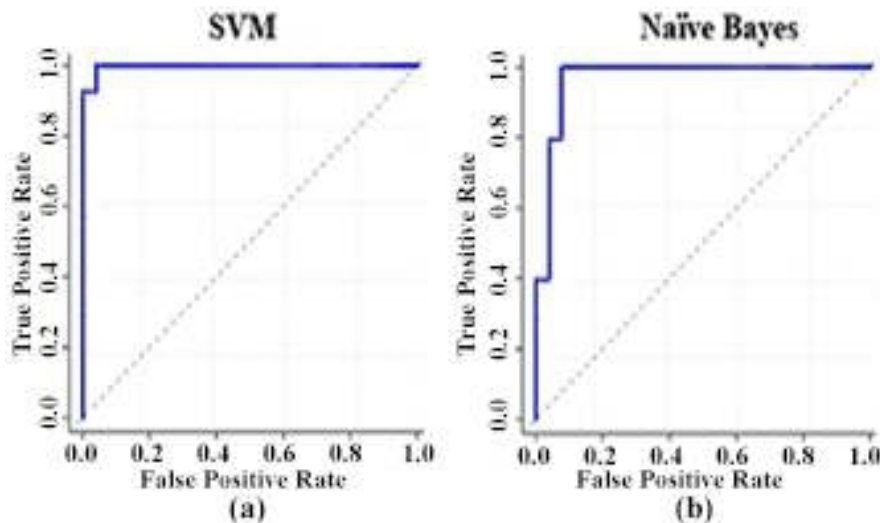


Fig. 10 ROC curves for SVM and NB classifier: (a) ROC curve for SVM; (b) ROC curve for NB

• Classification Phase

The proposed system was tested on a CT image dataset through used 12 pathological CT sets, divided into malignant (6 cases) and benign (6 cases). To evaluate the proposed classification performance several standard measures were used, as defined as (9)-(13):

$$\text{Accuracy (ACC)} = \frac{TP+TN}{TP+TN+FP+FN} \quad (9)$$

$$\text{Sensitivity (SE)} = \frac{TP}{TP+FN} \quad (10)$$

$$\text{Specificity (SP)} = \frac{TN}{TN+FP} \quad (11)$$

$$\text{Positive predictive value (PPV)} = \frac{TP}{TP+FP} \quad (12)$$

$$\text{Negative predictive value (NPV)} = \frac{TN}{TN+FN} \quad (13)$$

The result of the two experiments is presented in Table II; it shows that higher accuracy classification result is achieved when using the features difference between normal liver tissue around lesion and the lesion, compared with using absolute features from the lesion only. The ROC curve is presented in Fig. 9.

According to the experiment, the highest results obtained when used SVM classifier compared to NB, as painted in Fig. 10.

The baseline [13] is already introduced in detail in literature section. This baseline is selected since it is the most recent baseline. Moreover, it represents the state-of-art with its high accuracy. Due to the limited availability of the used dataset, we have regenerated the baseline by implementing [13] and applying it on our dataset. The results of the proposed system, compared to the baseline, are shown in Table III.

TABLE III
COMPARISON BETWEEN PROPOSED METHOD AND BASELINE

	Baseline		proposed method	
	M	B	M	B
ACC	91.7%	91.7%	98.3%	98.3%
SE	90.9%	92.6%	97%	100%
SP	92.6%	90.9%	100%	97%
PPV	93.8%	89.3%	100%	96.4%
NPV	89.3%	93.8%	96.4%	100%

The importance of the proposed system is the ability to classify the liver lesion into benign and malignant with the high accuracy 98.3% through the novelty of building feature vector based on the difference of feature between a lesion and normal liver tissue that surround the lesion

V.CONCLUSION

This paper proposed an automated CAD system that can perform the entire diagnostic process from the segmentation of the liver to the detection of a tumor and classification into *benign* and *malignant*. The novelty of the proposed approach is the ability of identifying the difference between the lesion and the surrounding normal tissues, based on extracting intensity and texture features from both. Then, the difference between features from both areas is utilised as the new feature vector and used in training a classifier. This features-difference has improved the accuracy to 98.3%. More importantly, it helps overcoming one of the major issues, namely the variation of intensity and texture ranges between different patients, ages, demographics and/or imaging devices. The proposed system can be extended for other types of liver diseases such as HCC, metastatic, cysts, and liver mass and also for other types of medical images like MRI.

REFERENCES

[1] A. Jemal, F. Bray, M. M. Center, J. Ferlay, E. Ward, and D. Forman, Global cancer statistics. *CA: A Cancer Journal for Clinicians*. 61, pp. 69–90. doi: 10.3322/caac.20107, 2011.

[2] A. P. Megha, "Recent Advances and Future Potential of Computer Aided Diagnosis of Liver Cancer on Computed Tomography Images," In *Computer Networks and Intelligent Computing*, pp. 246-251. Springer Berlin Heidelberg, 2011.

[3] P. Dankerl, A. Cavallaro, T. Alexey, M. Costa, M. Suehling, R. Janka, M. Uder, and M. Hammon. "A Retrieval-based computer-aided diagnosis system for the characterization of liver lesions in CT scans," *Academic radiology* 20, no. 12: pp.1526-1534, 2013.

[4] A. Militzer, T. Hager, F. Jager, C. Tietjen, and J. Hornegger. "Automatic detection and segmentation of focal liver lesions in contrast enhanced CT images," In *Pattern Recognition (ICPR), 2010 20th International Conference on*, pp. 2524-2527. IEEE, 2010.

[5] S. S. Kumar, R. S. Moni, and J. Rajeesh. "Liver tumor diagnosis by gray level and contourlet coefficients texture analysis," In *Computing, Electronics and Electrical Technologies (ICCEET), International Conference on*, pp. 557-562. IEEE, 2012.

[6] A. Depeursinge, C. Kurtz, C. Beaulieu, S. Napel, D. Rubin, "Predicting Visual Semantic Descriptive Terms From Radiological Image Data: Preliminary Results With Liver Lesions in CT," *Medical Imaging, IEEE Transactions on*, vol.33, no.8, pp.1669-1676, 2014.

[7] P. M. Taylor. "A review of research into the development of radiologic expertise: Implications for computer-based training," *Academic radiology* 14, no. 10, pp. 1252-1263, 2007.

[8] Y. Wei, Q. Feng, M. Huang, Z. Lu, and W. Chen. "A non-parametric method based on NBNN for automatic detection of liver lesion in CT images," In *Biomedical Imaging (ISBI), 2013 IEEE 10th International Symposium on*, pp. 366-369. IEEE, 2013.

[9] K. Mala, V. Sadasivam. "Wavelet based texture analysis of Liver tumor from Computed Tomography images for characterization using Linear Vector Quantization Neural Network," In *Advanced Computing and Communications, 2006. ADCOM 2006. International Conference on*, pp. 267-270. IEEE, 2006.

[10] K. Mala, V. Sadasivam. "Classification of Fatty and Cirrhosis Liver Using Wavelet-Based Statistical Texture Features and Neural Network Classifier," *International Journal of Software and Informatics* 4, no. 2, pp. 151-163, 2010.

[11] S. Gunasundari, S. Gunasundari, and M. Suganya Ananthi. "Comparison and Evaluation of Methods for Liver Tumor Classification from CT Datasets," *International Journal of Computer Applications* 39, no. 18, pp. 46-51, 2012.

[12] S. S. Kumar, R. S. Moni, and J. Rajeesh. "An automatic computer-aided diagnosis system for liver tumours on computed tomography images," *Computers & Electrical Engineering* 39, no. 5, pp. 1516-1526, 2013.

[13] Y. Doron, N. Mayer-Wolf, I. Diamant, and H. Greenspan. "Texture feature based liver lesion classification," In *SPIE Medical Imaging*, pp. 90353K-90353K. International Society for Optics and Photonics, 2014.

[14] W. Kuo-Lung, M. Yang. "Alternative c-means clustering algorithms," *Pattern recognition* 35, no. 10, pp.2267-2278, 2002.

[15] M. Yang, Y. Hu, K. C. Lin, and C. C. Lin. "Segmentation techniques for tissue differentiation in MRI of ophthalmology using fuzzy clustering algorithms," *Magnetic Resonance Imaging* 20, no. 2, pp. 173-179, 2002.

[16] Z. Binsheng, L. H. Schwartz, L. Jiang, J. Colville, C. Moskowitz, L. Wang, R. Leftowitz, F. Liu, and J. Kalaigian. "Shape-constraint region growing for delineation of hepatic metastases on contrast-enhanced computed tomograph scans," *Investigative radiology* 41, no. 10, pp. 753-762, 2006.

[17] P. Jaccard, "The distribution of the flora in the alpine zone. 1," *New phytologist* 11, no. 2, pp. 37-50, 1912.

[18] L. Dice, "Measures of the amount of ecologic association between species," *Ecology* 26, no. 3, pp. 297-302, 1945.

[19] R. Karsten, E. Bengtsson, "A feature set for cytometry on digitized microscopic images," *Analytical Cellular Pathology* 25, no. 1, pp. 1-36, 2003.

[20] J. Cao, H. Li, Q. Cai, and Shi-long Guo, "Research on Feature Extraction of Image Target," *Computer Simulation* 30, no. 1, pp. 409-413, 2013.

[21] A. Chadha, M. Sushmit, and J. Ravdeep, "Comparative Study and Optimization of Feature-Extraction Techniques for Content based Image Retrieval," *arXiv preprint arXiv*, pp.1208-6335, 2012.

[22] Cs.waikato.ac.nz, (2015). *Weka 3 - Data Mining with Open Source Machine Learning Software in Java*. (online) Available at: <http://www.cs.waikato.ac.nz/ml/weka/> (Accessed 19 Sep. 2015).



Hussein Alahmer born in 1982, has received his B.Sc. Degree in Computer science; his M.Sc. Degree in Information Technology from The University of Sunderland, UK in 2004 and 2012 respectively. He is a PhD researcher at School of Computer Science in University of Lincoln, UK and an assistant lecturer in Al balqa Applied University, Jordan; his current research interests include

Medical Image Processing, Segmentation, semantic analysis.



Amr Ahmed (BSc93, MSc98, PhD04, MBCS05, IEEE-CS08) is a Senior Lecturer, and the Founder and the Leader of the DCAPI (Digital Contents Analysis, Production, and Interaction: <http://dcapi.lincoln.ac.uk>) research group at the School of Computer Science, University of Lincoln, UK. His research focuses on the analysis, understanding, and interpretation of digital contents, especially visual contents.

Amr's current research interests include Contents-Based Image/Video retrieval, video and scene understanding, semantic analysis, integration of knowledge and various modalities for scene understanding. Amr worked in the industry for several years, including Sharp Labs of Europe (SLE), Oxford (UK), as a Research Scientist, and other Engineering Consultants companies abroad. He also worked as a Research Fellow, at the University of Surrey, before joining the academic staff the University of Lincoln in 2005. Dr. Ahmed is a Member of the British Computer Society (MBCS) and the IEEE Computer Society. He received his Bachelors degree in Electrical Engineering and M.Sc. degree (by research) in Computer and Systems Engineering, from Ain Shams University, Egypt, in 1993 and 1998 respectively, and his Ph.D. degree in Computer Graphics and Animation from the University of Surrey, U.K., in 2004.