

# The Clinical Use of Ahmed Valve Implant as an Aqueous Shunt for Control of Uveitic Glaucoma in Dogs

Khaled M. Ali, M. A. Abdel-Hamid, Ayman A. Mostafa

**Abstract—Objective:** Safety and efficacy of Ahmed glaucoma valve implantation for the management of uveitis induced glaucoma evaluated on the five dogs with uncontrollable glaucoma. **Materials and Methods:** Ahmed Glaucoma Valve (AGV®; New World Medical, Rancho Cucamonga, CA, USA) is a flow restrictive, non-obstructive self-regulating valve system. Preoperative ocular evaluation included direct ophthalmoscopy and measurement of the intraocular pressure (IOP). The implant was examined and primed prior to implantation. The selected site of the valve implantation was the superior quadrant between the superior and lateral rectus muscles. A fornix-based incision was made through the conjunctiva and Tenon's capsule. A pocket is formed by blunt dissection of Tenon's capsule from the episclera. The body of the implant was inserted into the pocket with the leading edge of the device around 8-10 mm from the limbus. **Results:** No post-operative complications were detected in the operated eyes except a persistent corneal edema occupied the upper half of the cornea in one case. Hyphaema was very mild and seen only in two cases which resolved quickly two days after surgery. Endoscopic evaluation for the operated eyes revealed a normal ocular fundus with clearly visible optic papilla, tapetum and retinal blood vessels. No evidence of hemorrhage, infection, adhesions or retinal abnormalities was detected. **Conclusion:** Ahmed glaucoma valve is safe and effective implant for treatment of uveitic glaucoma in dogs.

**Keywords—**Ahmed valve, endoscopy, glaucoma, ocular fundus.

## I. INTRODUCTION

GLAUCOMA is a common and potentially blinding complication of uveitis. The pathogenic processes responsible for an underlying elevation in intraocular pressure are often multiple and may include both open angle and closed angle mechanisms. When medical treatment fails, surgical intervention in the form of trabeculectomy with wound modulation therapy or drainage implantation is generally indicated [1].

Intraocular pressure regulation is the primary target in glaucoma management and is obtained either pharmaceutically (topical or systemic pressure-lowering drugs) or surgically (trabecular filtration surgery or drainage device implantation). Among the various surgical procedures, drainage devices have gained popularity mostly due to their ease of use, their efficacy in IOP reduction and due to the

Abdel-Hamid M. A, Ayman A. Mostafa, Khaled M. Ali (Corresponding author), lecturer of ophthalmology are with the Department of Surgery, Anesthesiology and Radiology, Faculty of Veterinary Medicine, Cairo University, Giza 12211, Egypt (phone: (202) 01008233425 / 35710306; e-mail: drkhaled\_ali@cu.edu.eg).

growing concerns about late complications associated with standard filtering surgery [1]-[2].

Various aqueous shunting devices, including restrictive and nonrestrictive implants, are used to manage complicated glaucoma that is resistant to medical therapy and traditional filtering surgery [3].

The non-restrictive (valveless) devices, such as Molteno and Baerveldt valves, consist of an implant with an open tube. The valveless device has been associated with the development of hypotony after the early postoperative period. The restrictive (valved) devices, such as Krupin and Ahmed, contain a design with restriction to flow to eliminate the incidence of hypotony [4].

## II. MATERIALS AND METHODS

### A. Animals

Five dogs with uveitic induced secondary open angle glaucoma were included in this study. The study protocol was approved by the Scientific Committee of the Department of Veterinary Surgery at Cairo University prior to enrollment of the dogs. Additionally, an approval of the study procedures and techniques was obtained according to guidelines and regulations for researches involving live animals.

### B. Anaesthesia

All surgeries were performed with the animal under general anaesthesia using Xylazine (1mg/Kg body weight, ADWIA, Egypt) and Ketamine Hcl (Protexmedica, Trittau, Germany) at a dose rate of 15mg/Kg body weight combined by retrobulbar injection of lidocaine 2%. The technique of retrobulbar anaesthesia was performed with the dog under general anaesthesia with the objective of forcing the globe further rostral in the orbit for more exposure of the sclera and to fix the globe. The needle was inserted caudal to the lateral orbital ligament and dorsal to the zygomatic arch.

### C. Ahmed Glaucoma Valve

Ahmed Glaucoma Valve (AGV®) is a flow restrictive, non-obstructive Self-regulating valve system. It provides resistance to the aqueous in order to prevent excessive drainage and chamber collapse. Ahmed glaucoma valve implant (New World Medical, Rancho Cucamonga, CA, USA) is composed of a silicon drainage tube (0.635-mm outer diameter, 0.317-mm inner diameter) and a 184mm polypropylene body (16 mm long, 13 mm wide and 1.9 mm thick). The body consists of a specially tapered chamber, with a large inlet to a small

outlet, to create a venturi-flow effect and to provide resistance to aqueous flow (Fig. 1).

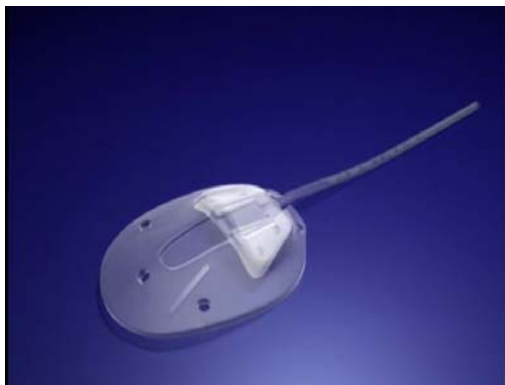

Fig. 1 Flexible plate (FP7) Ahmed valve

*Plate/Valve Specifications:*

- Thickness: 0.9mm.
- Width: 13.00mm.
- Length: 16.00mm.
- Surface Area: 184.00mm.

*Tube Specifications:*

- Length: 25.00mm.
- Inner Diameter: 0.305mm.
- Other Diameter: 0.635mm.

*Materials:*

- Valved Plate Body: medical-grade silicone.
- Drainage Tube: medical-grade silicone.
- Valve: medical-grade silicone, elastomer membrane.
- Valve Casing: medical-grade polypropylene.

*Surgical Technique:*

Preoperative ocular evaluation included direct ophthalmoscopy and intraocular pressure (IOP). The implant was examined and primed prior to implantation. Priming is accomplished by injecting 1cc balanced salt solution through the drainage tube of the valve using a blunt 26 gauge cannula. The selected site of the valve implantation was the superior quadrant between the superior and lateral rectus muscles. A fornix-based incision was made through the conjunctiva and Tenon's capsule. A pocket is formed by blunt dissection of Tenon's capsule from the episclera. The body of the implant was inserted into the pocket with the leading edge of the device around 8-10 mm from the limbus.

The drainage tube was then trimmed (bevel cut to an anterior angle of 30° to facilitate insertion) to permit a 2-3mm insertion of the tube into the anterior chamber (AC). The valve was sutured to the sclera with 6/0 nylon sutures passed through the fixation platform on both sides of the valve. A 2/3 thickness limbal based scleral flap has been made and the tube was inserted into the Anterior chamber. The flap was then closed using vicryl 6/0. The conjunctival wound was closed using vicryl 6/0 using by simple interrupted suture pattern.

*D. Post Operative Follow up*

The intraocular pressure of the operated animals was monitored for 3 successive months. The instrument of Schoitz tenometer (Riester®, Germany) with the 5.5 and 7.5 gm weights were used to obtain the readings [5]. Endoscopic camera was used to examine the anterior chamber and the fundus of the operated eyes; the technique of examination was based on the use of endoscopic probe {8.5mm diameter, Eickemeyer video endoscope unit supplied with halogen light source 150 watt (vetlux), Germany} [6].

*E. Stastical Analysis*

All statistical analysis were calculated with commercial software (SPSS, (ver. 15.0; SPSS Inc., Chicago, IL). Appropriate statistical analysis was done according to Snedecor and Cochran [7], for analysis of variance (ANOVA) test was used to check the Stastical significance at  $P < 0.05$  and 0.01 levels.

III. RESULTS

Slight corneal edema appeared in the superior lateral quadrant immediately after surgery (Fig. 2) and disappeared completely 5 days later. The menace, corneal and pupillary light reflexes were present but sluggish starting from the next day of surgery. The suture was resolved completely at the end of the second week postoperatively. The tube of the valve was clear and visible inside the anterior chamber and was surrounded by clotted blood which resolved 3 days after surgery.

Two weeks postoperatively, the conjunctival wound was completely healed and the device was invisible and can be easily felt under the conjunctiva (Fig. 3). The cornea appeared clear and the tube clearly seen within the anterior chamber. All reflexes of the eye were present and the animal can avoid objects when the non-operated eye was closed and reacted normally with any stimulus.

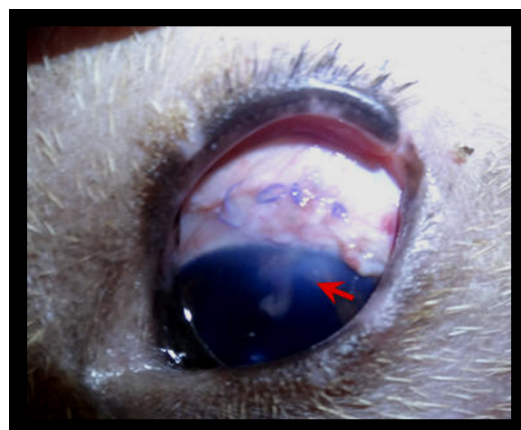


Fig. 2 The operated eye after Ahmed valve implantation 2 days after surgery showing the incision site, corneal edema ventral to the incision site and the tube inside the anterior chamber surrounded by clotted blood (arrow)

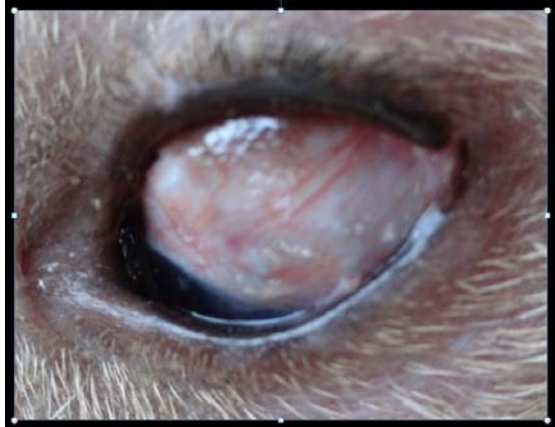

Fig. 3 The operated eye 2 weeks after Ahmed valve implantation showing complete healing of the incision site with the device invisible under the conjunctiva

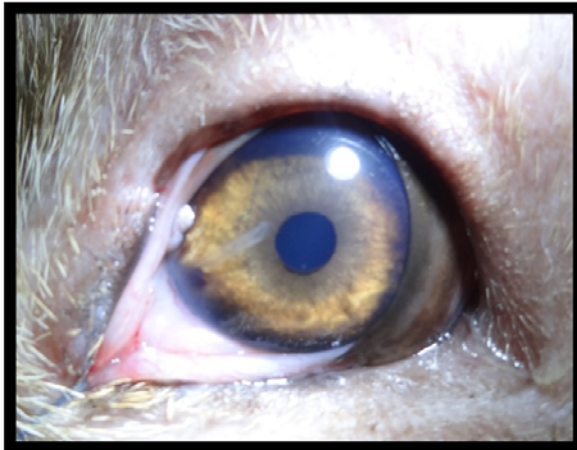


Fig. 4 The operated eye one month after Ahmed valve implantation showing clear cornea and disappearance of the corneal edema with the tube clearly visible inside the anterior chamber

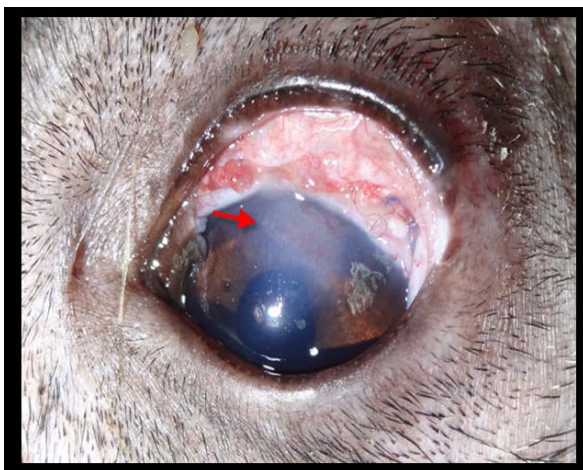


Fig. 5 Complicated case with corneal edema (arrow)

One month postoperatively the operated eye showed clear cornea with complete disappearance of the corneal edema, the tube was clearly visible inside the anterior chamber and the

sclera was apparently normal (Fig. 4). No post-operative complications were detected in the operated eyes except a persistent corneal edema occupied the upper half of the cornea for 3 weeks in one case (Fig. 5). Hyphaema was very mild and seen only in two cases which resolved quickly two days after surgery.

Endoscopic examination for the operated eyes revealed a normal ocular fundus with clearly visible optic papilla, tapetum and retinal blood vessels. No evidence of hemorrhage, infection, adhesions or retinal abnormalities was detected. The tube was free inside the anterior chamber without adhesions or corneal contact (Fig. 6). Endoscopic examination for the case with persistent corneal edema showed a traumatic adhesion between the iris and the tube of the valve (Fig. 7).

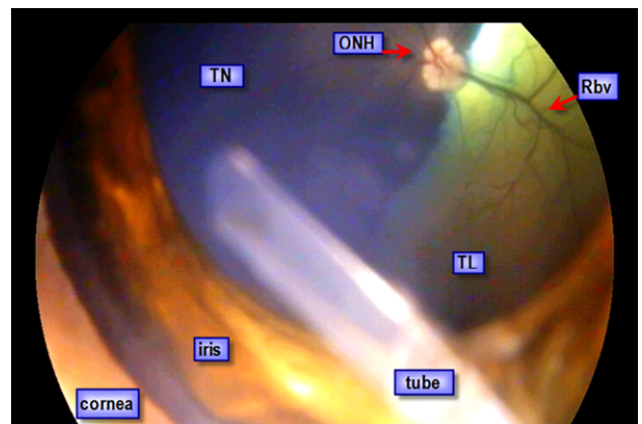


Fig. 6 Endoscopic photograph showing the anterior chamber and fundus of an eye two months after Ahmed valve implantation. ONH; optic nerve head, Rbv; retinal blood vessels, TN; tapetum nigrum, TL; tapetum lucidum

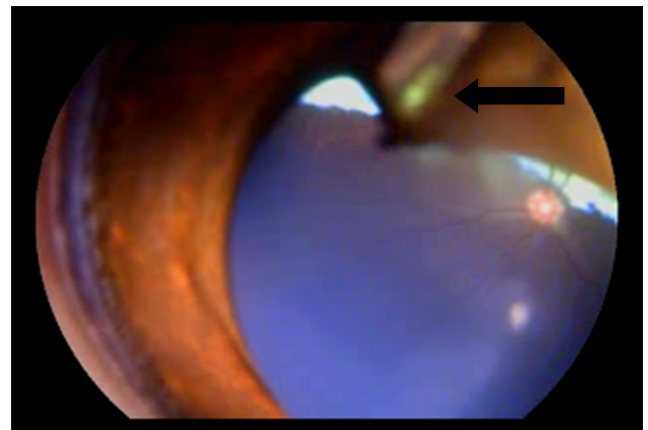


Fig. 7 Endoscopic photograph showing the anterior chamber and fundus of the case with persistent corneal edema and traumatic adhesion between the iris and the tube of the valve (arrow)

The intraocular pressure was monitored postoperatively for three successive months and was reduced immediately after operation and the mean reading was  $(13.5 \pm 1.057; 8\text{mmHg}$  at  $5.5\text{gm}$  and  $16.5 \pm 1.089; 8\text{mmHg}$  at  $7.5\text{gm}$ ) (Table I). The IOP continued to be low during the first week after surgery.



Starting from the second week the IOP rose to reach 18mmHg and it reached 21mmHg at the six week after surgery (Fig. 8). The IOP was stable starting from the six week with mean reading of (6.158 at 5.5 gm and 8.625 at 7.5 gm). The reading at the first week showed significant difference  $p < 0.01$  and was higher than readings of the other weeks. No significance difference was detected between IOPs of the second and third month after surgery.

TABLE I  
 THE MEAN READINGS (MEAN±SEM) OF SCHIÖTZ TONOMETER USING  
 WEIGHTS 5.5GM AND 7.5GM

Weeks	Reading at 5.5gm±SEM	Reading at 7.5gm±SEM
Week 1	13.5±1.057	16.5±1.089
Week 2	5.5±1.057	8±1.089
Week 3	4.5±1.057	7.5±1.089
Week 4	4.5±1.057	7.5±1.089
Week 5	6.5±1.057	8.5±1.089
Week 6	4±1.057	7±1.089
Week 7	5±1.057	7.5±1.089
Week 8	5.5±1.057	8±1.089
Week 9	6±1.057	8±1.089
Week 10	6±1.057	8.5±1.089
Week 11	6.5±1.057	8±1.089
Week 12	6±1.057	8.5±1.089
<b>Mean</b>	<b>6.158</b>	<b>8.625</b>
<b>Standard deviation</b>	<b>2.365</b>	<b>2.436</b>

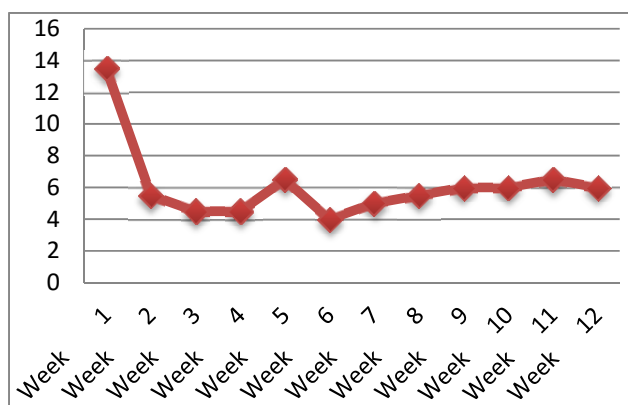


Fig. 8 The IOP from the first week to 12 weeks after Ahmed valve implantation using weight 5.5gm of Schoitz tonometer

#### IV. DISCUSSION

The concept of designing a drainage device for glaucoma control was introduced several decades ago [8]. Although these devices possess the potential to regulate the flow of drainage, complications associated with the procedure mean that is difficult for them to replace a traditional trabeculectomy as the primary treatment modality for glaucoma surgery. With improvements in the design, materials, and manufacturing deficiencies, the role of glaucoma drainage devices has progressively improved due to fewer problems with poor flow control and tissue compatibility [9].

In viewing the obtained results after Ahmed valve implantation a successful outcome was achieved in the majority of eyes with 3 months of follow up. According to the

previous literatures, the Ahmed glaucoma valve is associated with a higher incidence of the hypertensive phase, which peaked in the first month and had stabilized by 3 months after the operation [10]. Regarding this point, this study showed comparable results in that most incidences of the hypertensive phase were exhibited in the second month after surgery (21mmHg).

The higher incidence of the hypertensive phase could be related to the biomaterial and the shape and consistency of the end plate [11], [12]. It was suggested that the characteristics of the Ahmed glaucoma plate, being made of polypropylene with an extremely rigid consistency, may enhance more micro-motion in the postoperative period and attract white cells and collagen to grow on the surface of the plate, resulting in the formation of bleb fibrosis and subsequent elevation of IOP [10]-[12].

The degree of IOP reduction after glaucoma drainage implant surgery may be dependent on capsular thickness and the total surface area of encapsulation. Lower postoperative IOP is expected with a thinner capsule and larger surface area of the drainage device [13], [14]. In this study marked reduction in the IOP was observed after surgery (8mmHg) which continued to rise gradually on the commencement of the second week postoperatively (18mmHg).

There were no serious postoperative complications in this study except a persistent corneal edema occupied the upper half of the cornea for 3 weeks in one case which attributed to traumatic adhesion between the iris and the tube or to tube endothelial touch. Slight corneal edema appeared in the superior lateral quadrant immediately after surgery and disappeared completely 5 days later. Hyphaema was very mild and seen only in two cases which resolved quickly two days after surgery.

#### V. CONCLUSION

Ahmed glaucoma valve is safe and effective implant for treatment of uveitic glaucoma in dogs.

#### REFERENCES

- [1] K. S. Schwartz, R.K. Lee, and S.J. Gedde, Glaucoma drainage implants: a critical comparison of types. *Current Opinion in Ophthalmology*, 2006, 17: 181-189.
- [2] S. J. Gedde, J.C. W.J. Schiffman Feuer, L.W. Herndon, and J.D. Brandt, Treatment Outcomes in the Tube versus Trabeculectomy (TVT) Study After Five Years of Follow-up. *AJOPHT*, 2012, 153: 789-803.
- [3] R. P. Wilson, L. Cantor, L.J. Katz, C.M. Schmidt, W.C. Steinmann, and S. Allee, Aqueous Shunts. Moltano versus Schocket. *Ophthalmology*, 1992, (99):672-8.
- [4] S. W. Siegner, P.A. Netland, R.C. Urban, A.S. Silliams, D.W. Richards, M. A. Latina, and J.D. Brandt, Clinical experience with the Baeveldt glaucoma drainage implant. *Ophthalmology*, 1995, (102):1298-309.
- [5] P. E. Miller, and J.P. Pickett, Comparison of the human and canine Schiotz tonometry conversion tables in clinically normal cats. *Journal of the American Veterinary Medical Association*, 1992, 201:1017.
- [6] K. M. Ali, Studies on glaucoma in dogs. PhD thesis: Cairo University, Egypt. 2014.
- [7] G. W. Snedecor, and W.G. Cochran, Statistical methods. 6 Ed., Iowa state Univ. press, Iowa, U.S.A., 1976.
- [8] T. Krupin, S.M. Podos, and B. Becker, Valve implants in filtering surgery. A preliminary report. *Am J Ophthalmol*. 1976, 81:232-5.
- [9] A. C. B. Moltano, The optimal design of drainage implants for glaucoma. *Trans Ophthalmol Sc NZ*, 1981, 33:39-41.

- [10] R. P. Mills, A. Reynolds, M.J. Emond, W.E. Barlow, and M.M. Leen, Long-term survival of Moltenoof Molteno glaucoma drainage devices. *Ophthalmology*, 1996, 103:299-305.
- [11] R. S. Ayyala, L.E. Harman, A.F. Michelini-Norris, L.E. Ondrovic, E. Haller, C.E. Margo, and S.X. Stevens, Comparison of different biomaterials for the glaucoma drainage devices. *Arch Ophthalmol.*, 1999; 117:233-6.
- [12] R. S. Ayyala, A.F. Michelini-Norris, A. Flores, E. Haller, and C.E. Margo, Comparison of different biomaterials for glaucoma drainage devices. Part 2. *Arch Ophthalmol.*, 2000, 118:1081-4.
- [13] D. P. Taglia, T.W. Perkins, and R. Gangnon, Comparison of the Ahmed glaucoma valve, the Krupin eye valve with disk, and the double-plate Molteno implant. *J Glaucoma*, 2002, 11: 347–353.
- [14] R. S. Ayyala, D. Zurakowski, J.A. Smith, R. Monshizadeh, P.A. Netland, D.W Richards, and W.E. Layden, A clinical study of the Ahmed Glaucoma Valve implant in advanced glaucoma. *Am.,J.*, 1998, (105);1968-76.