

Online Optic Disk Segmentation Using Fractals

Srinivasan Aruchamy, Partha Bhattacharjee, Goutam Sanyal

Abstract—Optic disk segmentation plays a key role in the mass screening of individuals with diabetic retinopathy and glaucoma ailments. An efficient hardware-based algorithm for optic disk localization and segmentation would aid for developing an automated retinal image analysis system for real time applications. Herein, TMS320C6416DSK DSP board pixel intensity based fractal analysis algorithm for an automatic localization and segmentation of the optic disk is reported. The experiment has been performed on color and fluorescein angiography retinal fundus images. Initially, the images were pre-processed to reduce the noise and enhance the quality. The retinal vascular tree of the image was then extracted using canny edge detection technique. Finally, a pixel intensity based fractal analysis is performed to segment the optic disk by tracing the origin of the vascular tree. The proposed method is examined on three publicly available data sets of the retinal image and also with the data set obtained from an eye clinic. The average accuracy achieved is 96.2%. To the best of the knowledge, this is the first work reporting the use of TMS320C6416DSK DSP board and pixel intensity based fractal analysis algorithm for an automatic localization and segmentation of the optic disk. This will pave the way for developing devices for detection of retinal diseases in the future.

Keywords—Color retinal fundus images, Diabetic retinopathy, Fluorescein angiography retinal fundus images, Fractal analysis.

I. INTRODUCTION

DIABETIC RETINOPATHY (DR) is one of the most devastating retinal diseases which occur due to the molecular pathogenesis of diabetes. It damages the small blood vessels in the retina, resulting in partial or complete loss of vision. Retinal fundus images are used by the ophthalmologist to identify the abnormalities in the retina. The detection and positioning of Optic Disc (OD) is a crucial step in detecting macular edema [1] and other abnormalities like glaucoma [2]. OD is the brightest part of the retinal image, and it has the size of 1.7 mm -1.9 mm [3] depicted in Figs. 1 (a) and (b). The size of the large exudates is similar to OD and so at times becomes difficult to distinguish the OD from exudates. Hence, to circumvent this issue a special algorithm is needed to filter out large exudates and locate the exact position of the optic disc for Mass Screening of DR.

Several reports have been documented in the literature on different methods in automated optic disk segmentation for screening of DR. Circular matched filter is used to segment OD by computing the cross-correlation with a pre-computed region of Interest [4]. Thresholding and morphological

processing (dilation and erosion) are also used as tools for the detection the OD [5]. Localize the OD was also carried out through Iterative thresholding and principal component analysis [6]. Ahmed et al. reported a new strategy where the two-dimensional problem of the optic disk segmentation was transformed into two one-dimensional problems. They have segmented the image into a number of vertical vessels and assumed that the vessel having maximum brightness is nearest to the OD. Moreover, the horizontal blood vessels are unlikely to be near the OD as most of the blood vessels from the OD are going in an upward or downward direction [7].

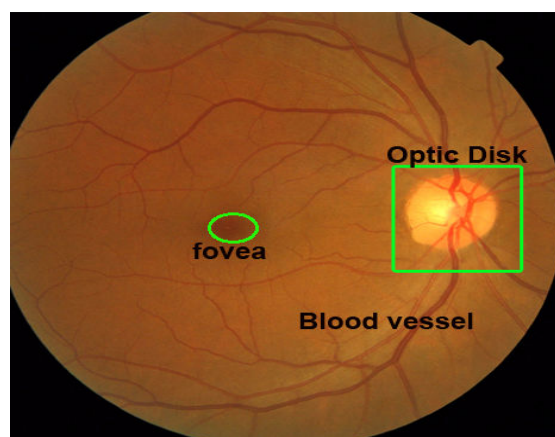


Fig. 1 (a) Color retinal fundus image

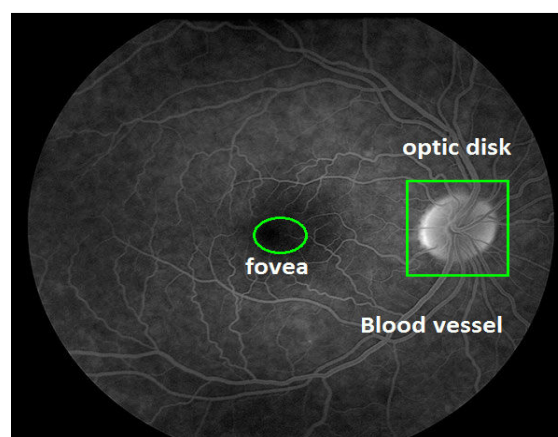


Fig. 1 (b) Fluorescein Angiography retinal images

The Directional pattern of retinal blood vessels is used for the detection of the optic disk. In their method, they used 2D Gaussian matched filter to segment the blood vessels, and the center of the OD is obtained based on the local intensity values [8]. Thanapong Chaichana et al. [9] identified the optic disk using the combination of canny edge detection and Hough transform [10], [11]. Through canny edge detection,

Srinivasan Aruchamy is with the CSIR-Central Mechanical Engineering Research Institute, Durgapur, India (phone: 0343-6452228; e-mail: srinivasapsg@gmail.com).

Partha Bhattacharjee is with the CSIR-Central Mechanical Engineering Research Institute, Durgapur, India (e-mail: partha11cmeri@gmail.com).

Goutam Sanyal is with the National Institute of Technology, Durgapur, India, (e-mail: nitsganyal@gmail.com).

the edges were detected and Hough transform is used for detecting a circle in the image. This method has been claimed (by the authors) to work better when binary images have less straight lines. This technique works on the brute force method [12]. As a result, it takes more computation time when a binary image has more straight lines. Thresholding technique and Hough transform have been used to detect the round elements in the retinal images from which, they traced the optic disk [13]. A geometrical parametric model is used for detecting OD by experimental data samples, where they constructed parabolic curves based on the flow of retinal blood vessels and identified OD parameters by the means of a simulated annealing optimization technique [14], [15]. They achieved 97.5 % correctness, and it took 5 minutes to extract the blood vessels and 2 minutes to detect the optic disk. Vahabi Z et al. [16] proposed a method that includes several techniques, like Wavelet-domain based image-pre-processing filter, Sobel edge detection, texture analysis and finally template matching to detect the OD. Xiaoying Yang et al. [17] used Gaussian vessel detector with contrast tuning for detecting the retinal vessels. Subsequently through morphological operation they detected the OD. Reza Pourreza-Shahri et al. [18] experimented with both color retinal fundus images and fluorescein angiography retinal fundus images. They used the radon transformation with multi-overlapping windows under an optimization framework to detect OD.

The present work tries to localize the optic disk before even segmentation. A novel method have been developed, which reduces the area of the image by cutting out several insignificant parts of the image, which are likely to be far from the OD in a number of steps. Edge detection is performed on the reduced image. Then a pixel intensity based fractal analysis [19], [20] is performed to locate the origin of the blood vessels which is nothing but the position of OD. Three publicly available retinopathy databases [22]-[24] and one private hospital database have been used to establish the accuracy of the proposed algorithms. Fig. 2 depicts the overall method.

II. PRE-PROCESSING

Retinal images captured from fluorescence ophthalmoscope are of low gray level contrast because of poor or non-uniform lighting condition, lack of linearity and limitation of the dynamic range of imaging sensor. Therefore, it is necessary to enhance the contrast of these images to make the subsequent image analysis easier. Contrast Limited Adaptive Histogram Equalization [21] (CLAHE) is a common pre-processing method for medical imaging, as it is very effective in making the region of interest more visible.

In this part, the retinal fundus image is divided into sub-images based on the window size (n). The window size n is determined based on the knowledge of the Optic disk size and a maximum diameter of the Optic disk obtained from the database. While calculating the window size scaling factor of the imaging system is also taken into consideration.

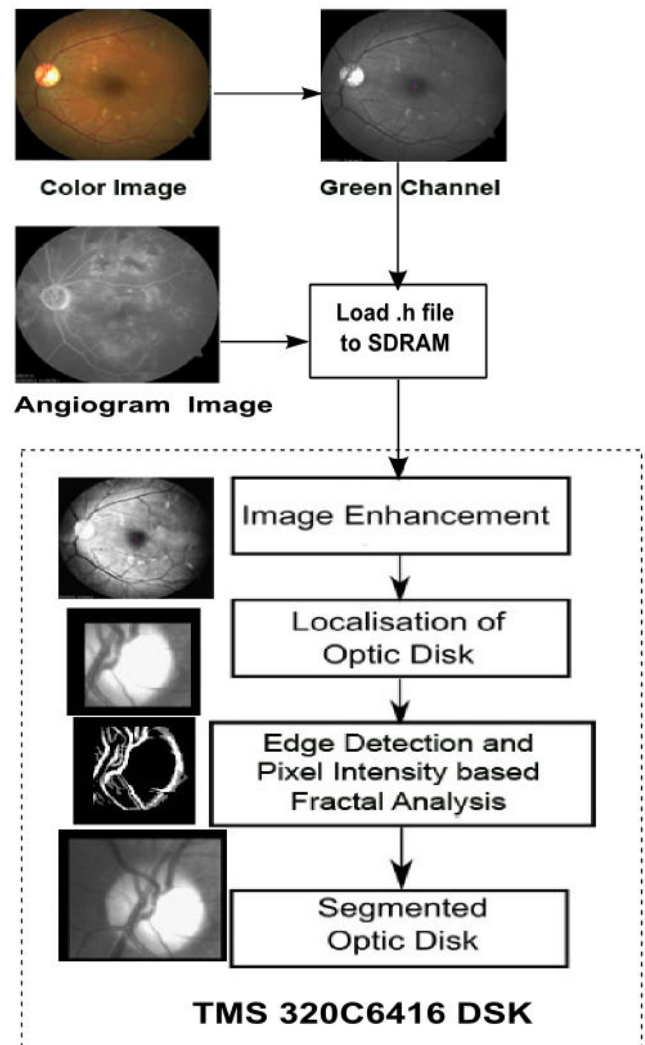


Fig. 2 Schematic overview of proposed method

Based on the real life data available from DRIVE and STARE database [22], [23] the n was chosen to be 79 and 130 pixels respectively. As the intensity values of the pixels on the Optic disk is very high compared to other parts of the image, it was divided into n uniform windows and then computed the mean of each window using (1):

$$m(i) = 1/N \sum_{k=0}^N I(k) \quad (1)$$

where m (i) is mean of the ith window, N is the total number of pixels in the ith window. Then the optic disk is located based on the highest mean. But when a number of exudates are more in case of DR, one window may not be able to locate optic disc properly. Also, one window of prescribed size may not cover the whole of the optic disk. Through repeated experiments, it has been observed that the window size needs to be at least 3/4th of the optic disk for detecting and locating it. Figs. 3 (a) and (b) depict the localized optic disk from the green channel retina image.

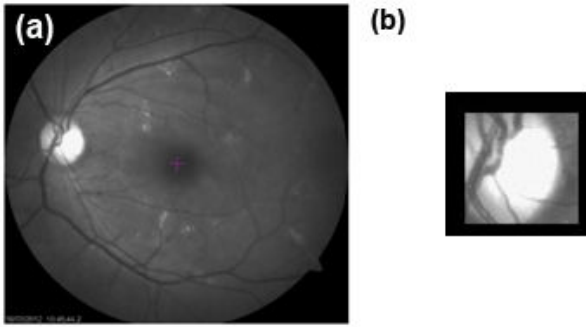


Fig. 3 (a) Green channel image (b) Localized image

After localization of OD, the edges were extracted by canny edge detection technique. Fig. 4 shows the edge detected image from localized image.

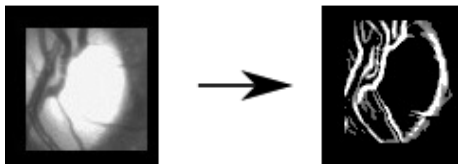


Fig. 4 Edge detected image from localized image

III. PIXEL INTENSITY BASED FRACTAL ANALYSIS

To improve the effectiveness of the implemented algorithm, the optic disc is localized. Pixel intensity based fractal analysis is performed to find the origin of the vascular tree. The retinal vascular tree possesses the property of self - similarity [19] like fractals as illustrated in Fig. 5 (a).

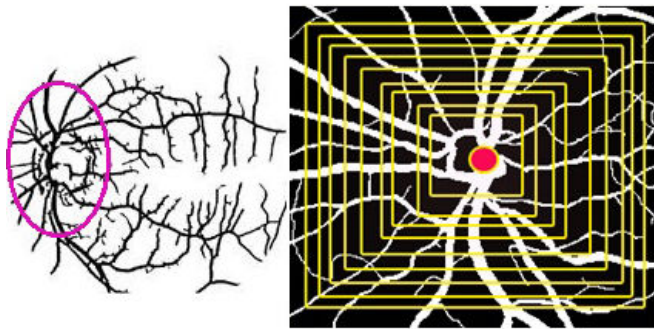


Fig. 5 (a) Vascular tree as a fractal structure, 5 (b) Vascular tree covered with boxes

The Pixel intensity based box counting method was used to calculate the fractal dimension. Further, this technique was used to find a pixel of the vascular tree which has many concentrated white pixels in the neighborhood. The pixel intensity based box counting method works on the principle of boxes laid over a localized image concentrically focused on each pixel of interest (as depicted in Fig. 5 (b)). The slope of the logarithmic function is called box dimension and it gives an appropriate approximation of the fractal dimension. The fractal dimension d is calculated as shown in (2):

$$d = \lim_{s \rightarrow 0} \frac{\log(n)}{\log(\frac{1}{s})} \quad (2)$$

where n is the number of boxes required to cover the fractal and s is the length of the box. The fractal analysis has been performed on every pixel present in the localized portion of the vascular tree. Based on that the pixel having the maximum fractal dimension (i.e. 1.85 ± 0.10) is selected as the origin of the vascular tree. Fig. 6 represents the graphical plot of fractal dimension of the retinal vascular tree. The horizontal axis represents the natural log of length r ($=1/s$) of the boxes and the vertical axis represents the natural log of the number of boxes required to cover the entire fractal set.

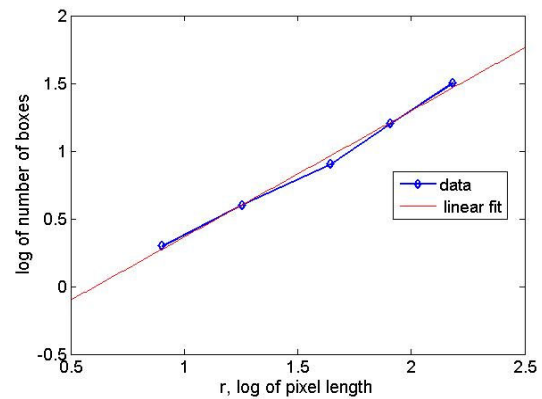


Fig. 6 Fractal dimension with linear fit

IV. IMPLEMENTATION

The proposed method was implemented in two different platforms. The first one was with Matlab running on an Intel(R) Xeon(R) PC with 2.40 GHz processor and 16 GB memory. The second method was implemented in a digital signal processing board TMS320C6416DSK DSP [25], having following features, clock rates of up to 1 GHz, 16 MB of SDRAM and 512 KB of NV Flash Memory with JTAG interface for host communication. Code composer studio is used as a host interface to exchange control information and data. The DSP STAR TFT LCD Video Daughter card (VM3224K2) is a video in/out hardware module, used for online image processing application. The artificial eye ball has been designed and developed where retinal images can be placed and captured using the high definition digital colour CCTV camera. The complete experimental setup is shown in Fig. 7.

For online optic disk segmentation, the retinal images were taken from private hospital data set and placed in the artificial eye ball. The prototype of eye ball developed in our laboratory was used for this experiment. The retinal images in the form of analog video signals were captured from the artificial eye ball through CCTV camera and processed using Philips SAA7113 video decoder to provide YUV 4:2:2 format data. This format was converted to a RGB565 image format. Further, it has been converted to a one-dimensional image strip. The processed image strip was then loaded into SDRAM of the DSP board. Fig. 2 depicts the detailed algorithm

followed to obtain OD for both color retinal fundus images and fluorescein angiography retinal fundus image. Fig. 8 shows the schematic view of online OD segmentation.




Fig. 7 Experimental setup

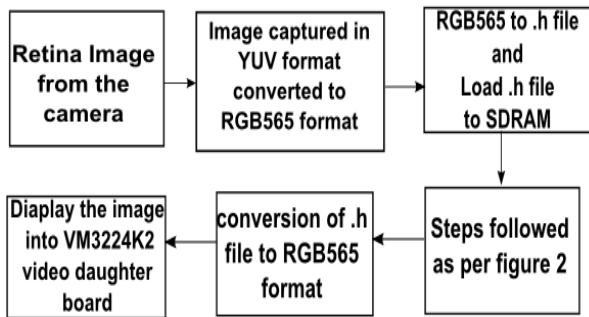


Fig. 8 The simplified work flow of online OD Segmentation

A. Computational Time Complexity Calculation

The input image of size $M \times N$ and Window size n with the algorithm steps p and the number of operations performed are as follows

1. The Pre-processing of retina image: MN
2. Localization of optic disk: MN
3. Pixel intensity based fractal analysis: $(MN/16)p\Theta$, where Θ indicates the pixel intensity based fractal calculation.
4. Segmentation of optic disk: $4 \Theta k$, where k indicates number of windows to be considered for segmentation in so the total number operations required to segment OD is $MN+MN+ (MN/16) p\Theta + 4 \Theta k$.

V. RESULT AND DISCUSSION

The color retinal images were taken from three publicly available data sets and a private hospital data set. The STARE Dataset (605X700 pixels) [22] consists of 81 images which include 50 abnormal images and 31 normal images. DRIVE dataset (565 X 584 pixels) [23] consist of 40 images in which 33 images were normal images and 7 were DR-affected images. The last data set is DIRETDB (1500 X 1152 pixels) [24] which consist of two different data sets. DIRETDB0 consists of 130 images and DIRETDB1 consists of 89 images and they were tested in this work. The private hospital data set consist of 150 images (82 color images and 68 FA images). 82 color retinal images include 62 DR-affected and 20 normal

images. These images were obtained through TOPCON (TRC-50EX) retinal camera having 50° field of view with a resolution of 2056 X 2124 pixels. An established ophthalmologist marked the Optic disks in these images and those were taken to assess the efficacy of the developed algorithm. The accuracy and computational time of the proposed method using these databases are summarized in Table I.

TABLE I
 RETINAL DATABASE AND CORRESPONDING DETECTION RATE

Image Data Base	No. of Images	Success	Accuracy Rate
STARE	81	78	96.2%
DRIVE	40	37	92.5%
DIARETDB	219	214	97.7%
Disha hospital (color Images)	82	79	96.3%
Disha hospital (FA Images)	68	61	89.7%

The number of images in each database is also indicated. The detection rate of fluorescein angiography images was less compared to color retinal image because single fluorescein angiography image has more than one bright region. The Success rate of detection is found to be 89.7%.

Figs. 9-12 show the successful optic disk segmentation samples.

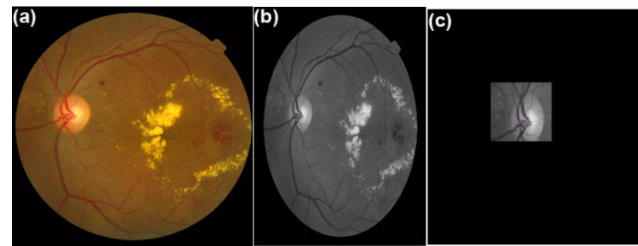


Fig. 9 (a) Image DR symptoms (b) CLAHE Image (c) Optic disk

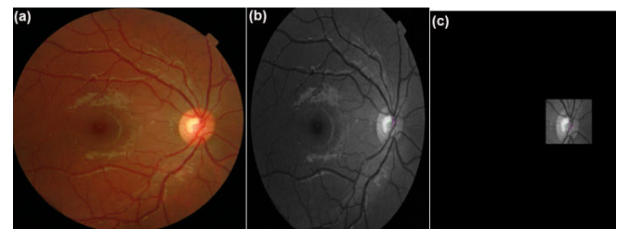


Fig. 10 (a) Normal Image (b) CLAHE Image (c) Optic disk

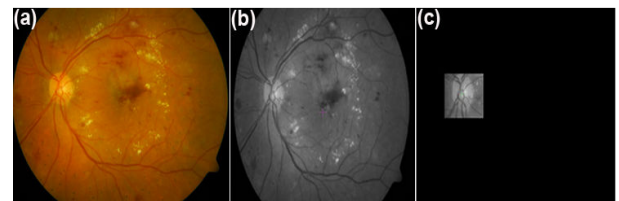


Fig. 11 (a) Image DR symptoms (b) CLAHE Image (c) Optic disk

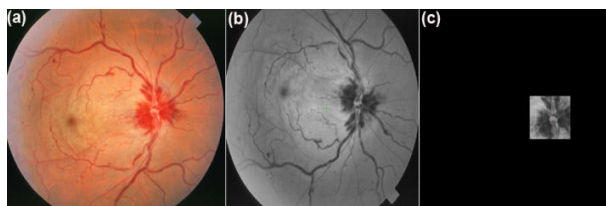


Fig. 12 (a) Image with OD damaged (b) CLAHE Image (c) Optic disk

Fig. 13 shows failed image samples. These images are considered to be lacking of oval like shape, so the proposed method failed to detect the OD. In the images shown in Fig. 13, OD is completely damaged and the pixel intensity based fractal analysis is not possible to identify the origin of retinal vessel tree. Figs. 14-16 show the FA images and Fig. 17 shows the failed FA images.

The accuracy of the pixel intensity based fractal analysis method and against existing methods is shown in Table II. The comparison in-terms of detection rate, computation time, mode of analysis and image type are listed in this table for STARE database. The methods described in [7], [14] has high detection rate, but they consume high computation time. Most of the existing methods reported in the literature are tested with offline mode only. Unlike those reported in the literature, the proposed method has been tested both online and offline. The results show considerable improvement in detection rate as well as computation time. The proposed method provides a considerable advantage over other methods for online screening of DR and Glaucoma.

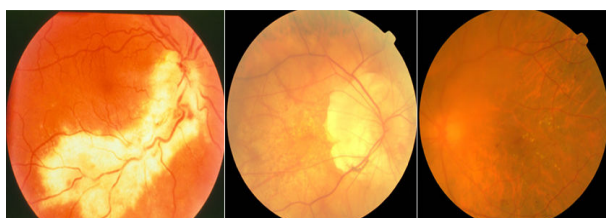


Fig. 13 Failed Images

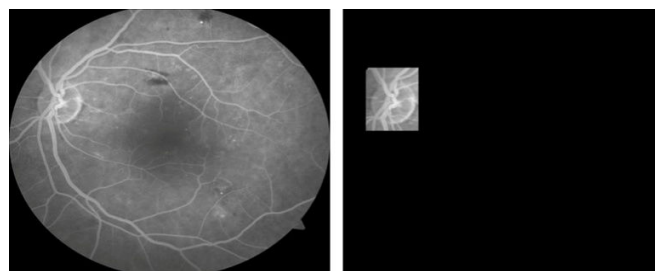


Fig. 14 (a) FA Normal Image (b) Optic disk

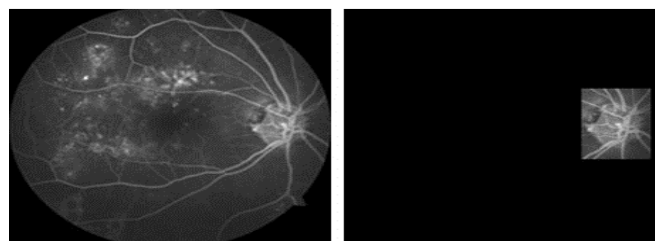


Fig. 15 (a) FA image with DR symptoms (b) Optic disk

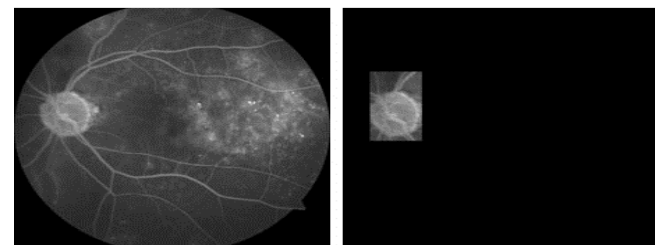


Fig. 16 (a) FA image with DR symptoms (b) Optic disk

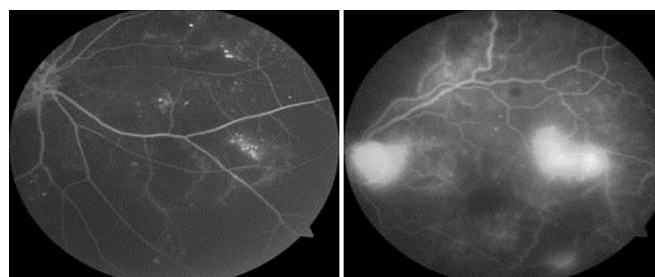


Fig. 17 Failed Images

TABLE II
DETECTION RATE AND MODE OF ANALYSIS COMPARISON FOR STARE DATABASE

Method	Detection Rate	Computation time	Mode of analysis	Image type
Youssif et al [8]	98%	3.5 min	Offline	Colour
Foracchia et al [14]	97.5%	7 min	Offline	Colour
Xiaoying Yang et al. [17]	91.3 %	27 seconds	Offline	Colour
Mira Park et al [13]	90.25%	4 sec	Offline	Colour
Reza Pourreza Shahri et al [18]	96.3%	2.9 sec	Offline	Colour and angiogram
Proposed method (using DSP Implementation)	96.2%	15.7 milli sec	Online and Offline	Colour and angiogram
Proposed method (Using Matlab)	96.2%	2.4 Sec	Offline	Colour and angiogram

VI. CONCLUSION

A novel and a facile strategy for optic disk segmentation is presented and implemented using simulation software as well as dedicated hardware platforms for mass screening of diabetic retinopathy and glaucoma. This method reduces the

computation time significantly to locate the optic disk. Usage of the special hardware (TMS320c6416) also enhances the speed of the detection process to a large extent. The proposed method also found to be more accurate and demonstrated greater improvement in online screening. The future scope of

this work is interfacing the retinal image acquisition system into the DSP processor, which will provide real-time results of the optic disk segmentation. Intricate mathematical modeling can be done to improve FA image segmentation.

ACKNOWLEDGMENT

This work is carried out under the financial support from CSIR, New Delhi (Project No: ESC0203/3). The authors are highly grateful to Dr. Debdulal Chakraborty, Consultant (Incharge Vitreo Retina Services), Disha Eye Hospital Kolkata for his professional help to this research work.

REFERENCES

- [1] T. Walter, J. -C Klein, P.Massin, and A.Erginay, "A Contribution of Image processing to the Diagnosis of Diabetic Retinopathy - Detection of Exudates in Color Fundus Images of the Human Retina," *IEEE Transaction on Medical Imaging*, vol. 21, no. 10, October 2002, pp. 1236-1243.
- [2] Crawford ML, Harwerth RS, Smith EL 3rd, Mills S, Ewing B, "Experimental glaucoma in primates: changes in cytochrome oxidase blobs in V1 cortex," *Invest Ophthalmol Vis Sci* 2001; 42: 358-64.
- [3] Duane's Ophthalmology, Lippincott Williams & Wilkins, 2006.
- [4] M.Ali Akber Dewan, Mohammad Shamsul Arefin, Muhammad Ahsan Ullah, Oksam Chae, "Automatic Extraction of Features from Retinal Fundus Image," *International Conference on Information and Communication Technology*, March 2007, Dhaka, Bangladesh.
- [5] Dimitris Koukounis, Lindsay Nicholson, David R. Bull and Alin Achim, "Retinal Image Registration Based on Multiscale Products and Optic Disc Detection," *33rd Annual International Conference of the IEEE EMBS*, Boston, Massachusetts USA, 2011.
- [6] Jihene Malek, Mariem Ben Abdallah, Asma Mansour and Rached Tourki, "Automated Optic Disc Detection in Retinal Images by Applying Region-based Active contour Modeling a variational Level Set Formulation," *International Conference on Computer Vision in Remote Sensing (CVRS)*, 2012.
- [7] Ahmed Essam Mahfouz and Ahmed S. Fahmy, "Ultrafast optic disc localization using projection of image features," *16th IEEE International Conference on Image Processing (ICIP)*, 2009.
- [8] Youssif A, Ghalwash A Z, Ghoneim A R, "Optic Disc Detection From Normalized Digital Fundus Images by Means of a Vessels' Direction Matched Filter," *IEEE Transaction on medical Imaging*, Vol 27, No. 1 January 2008.
- [9] Thanapong Chaichana, Sarat Yoowattana, Zhonghua Sun, Supan Tangjitkusolmun, Supot Sookpotharom and Manas Sangworasil, "Edge Detection of the Optic Disc in Retinal Images Based on Identification of a Round Shape," *IEEE International Symposium on Communication and Information Technologies*, 2008.
- [10] Xiangjian He, Jianmin Li, Darning wer, Wenjing Jia, Qiang Wu." Canny Edge Detection on a Virtual Hexagonal Image Structure", *proceedings of IEEE Joint Conferences on Pervasive Computing (JCPC)*, 2009.
- [11] Jean E. Vuillemin, "Fast Linear Hough Transform," *International Conference on Application Specific Array Processors*, 1063-6862/94 IEEE.
- [12] Ezedeen Kodeekha, "Brute Force Method for Lot Streaming in FMS Scheduling Problems," *11th International Conference on Intelligent Engineering Systems* - 29 June - 1 July 2007 - Budapest, Hungary
- [13] Mira Park, Jesse S. Jin and Suhuai Luo, "Locating the Optic Disc in Retinal Images," *Proceeding of the International Conference on Computer Graphics, Imaging and visualization, (CGIV'06)*0-7695-2606-3/06.
- [14] M. Foracchia, E. Grisan, and A. Ruggeri, "Detection of Optic Disc in Retinal Images by Means of a Geometrical Model of Vessel Structure," *IEEE Transactions on Medical Imaging*, VOL. 23, NO. 10, OCTOBER 2004.
- [15] R. Brunelli, "Optimal histogram partitioning using a simulated annealing technique," *Pattern Recognition Letters*, 13(1992) 581-586.
- [16] Vahabi Z, Vafadoost M and Gharibzadeh Sh, "The new approach to Automatic detection of Optic Disc from non-dilated retinal images," *Proceedings of the 17th Iranian Conference of Biomedical Engineering (ICBME2010)*, 3-4 November 2010, 978-1-4244-7484-4/10.
- [17] Xiaoying Yang, Satoshi Hamaguchi, Yan Sun, Shuangjiu Xiao, "Detection of Optic Disc Center based on Gaussian Vessel detector and Tangent Information Transform," *4th International Conference on Biomedical Engineering and Informatics (BMEI)*, 978-1-4244-9352 4/11/\$26.00 ©2011 IEEE.
- [18] Reza Pourreza-Shahri, Meysam Tavakoli, Nasser Kehtarnavaz, "Computationally efficient optic nerve head detection in retinal fundus images," *Biomedical Signal Processing and Control* 11 (2014) 63-73, 1746-8094/© 2014 Elsevier Ltd.
- [19] Gabriel Landini, Philip I. Murray, and Gary P. Missonf, "Local Connected Fractal Dimensions and Lacunarity Analyses of 60° Fluorescein Angiograms," *Investigative Ophthalmology Visual Science*, December 1995, Vol. 36, No. 13.
- [20] Guilherme M. Tosoni, DDS, PhD, Alan G. Lurie, DDS, PhD, Ann E. Cowan, PhD, and Joseph A. Burleson, PhD," Pixel intensity and fractal analyses: detecting osteoporosis in perimenopausal and postmenopausal women by using digital panoramic images," *Oral Surg Oral Med Oral Pathol Oral Radiol Endod* 2006;102:235-41
- [21] K. Zuiderveld, "Contrast limited adaptive histogram equalization," *Graphics gems*, vol. IV, pp. 474-485, 1994. J. G
- [22] <http://www.parl.clemson.edu/~ahoover/stare/index.html>.
- [23] Standard Diabetic Retinopathy Database Calibration Level 1. Retrieved June 22, 2011 from <http://www2.it.lut.fi/project/imageret/diaret/db1/>.
- [24] <http://www.isi.uu.nl/research/Databases/DRIVE>
- [25] <http://www.ti.com/product/tms320c6416>.

Srinivasan Aruchamy born in May 1982 in Coimbatore, Tamil nadu, India has received B.E degree in Computer Science and Engineering from Amrita Institute of Technology, Coimbatore. He obtained M.E in Computer Science and Engineering from P.S.G college of Technology, Coimbatore. Presently he is working in with CSIR-CMERI and doing Part time PhD from National Institute of Technology, Durgapur, West Bengal.

Partha Bhattacharjee, born in December 1962 in Kolkatta, West Bengal, India has received his B.Tech degree in Computer Science and Engineering from Indian Institute of Technology, Kharagpur. He obtained his PhD from National Institute of Technology, Durgapur. Presently he is working with CSIR-CMERI, Durgapur as a Senior Principal Scientist. He has published number of paper and patents. His area of interest includes computer networks, Medical Electronics, Medical Image Analysis.

Goutam Sanyal is designated as Professor and Dean in Department of Computer Science and Engineering. His qualifications are Bachelors of Engineering (B.E), Masters of technology (M.TECH), PhD(Engineering), FIE(India), MIEEE. Dr. Goutam Sanyal has more than 150 journals and research papers. He has a work experience of 28 years in Teaching and research and along with PhD Guidance. His area of interests is Computer Architecture, Computer Graphics, Computer Vision, Image Processing, VLSI, Mathematical Modelling and Simulation.