

# Evaluation of Azo Dye Toxicity Using Some Haematological and Histopathological Alterations in Fish *Catla catla*

Barot Jagruti

**Abstract**—The textile industry plays a major role in the economy of India and on the other side of the coin it is the major source for water pollution. As azo dyes is the largest dye class they are extensively used in many fields such as textile industry, leather tanning industry, paper production, food, color photography, pharmaceuticals and medicine, cosmetic, hair colorings, wood staining, agricultural, biological and chemical research etc. In addition to these, they can have acute and/or chronic effects on organisms depending on their concentration and length of exposure when they discharged as effluent in the environment. The aim of this study was to assess the genotoxic and histotoxic potentials of environmentally relevant concentrations of C. I. Reactive Red 120 (RR 120) on *Catla catla*, important edible freshwater fingerlings. For this, healthy *Catla catla* fingerlings were procured from the Government Fish Farm and acclimatized in 100 L capacity and continuously aerated glass aquarium in laboratory for 15 days. According to APHA some physico-chemical parameters were measured and maintained such as temperature, pH, dissolved oxygen, alkalinity, total hardness. Water along with excreta had been changed every 24 hrs. All fingerlings were fed artificial food pellets once a day @ body weight. After 15 days fingerlings were grouped in 5 (10 in each) and exposed to various concentrations of RR 120 (Control, 10, 20, 30 and 40 mg.l<sup>-1</sup>) and samples (peripheral blood and gills, kidney) were collected and analyzed at 96 hrs. All results were compared with the control. Micronuclei (MN), nuclear buds (NB), fragmented-apoptotic (FA) and bi-nucleated (BN) cells in blood smears and in tissues (gills and kidney cells) were observed. Prominent histopathological alterations were noticed in gills such as aneurism, hyperplasia, degenerated central axis, lifting of gill epithelium, curved secondary gill lamellae etc. Similarly kidney showed some detrimental changes like shrunken glomeruli with increased periglomerular space, degenerated renal tubules etc. Both haematological and histopathological changes clearly reveal the toxic potential of RR 120. This work concludes that water pollution assessment can be done by these two biomarkers which provide baseline to the further chromosomal or molecular work.

**Keywords**—*Catla catla*, genotoxicity, histopathological changes, RR 120 azo dye.

## I. INTRODUCTION

TEXTILE industries contribute major financial role to Indian economy as India is one of the largest textile hubs. Rapid industrialization and market demands have replaced natural dyes with synthetic one. Azo dyes is largest dye class

Jagruti Barot is with the Department of Biosciences, Veer Narmad South Gujarat University, Surat 395 007, Gujarat, India (phone: 09662062380; e-mail: jagruti.surati@gmail.com).

Jagruti Barot thanks to University Grant Commission, India for financial support.

among all synthetic dyes as they have properties like good fastness, brightness, wide ranges of colors, easy application as well as are of low cost [1]. Not only in textile industries they are also being utilized in many industries such as leather tanning industry, paper and pulp, food, color and paint, photography, pharmaceuticals and medicine, cosmetic, hair colorings, wood staining, agricultural, biological and chemical research etc.

Textile processes consume large amounts of water along with many toxic products. They contribute to the deterioration of the environment by releasing untreated or partially treated dye effluents into neighboring aquatic bodies [2]. The final disposal of this effluent remains a challenge, and its ecotoxicological evaluation is important for minimizing its environmental impacts. Approximately 10-15% of the dyes are discharged into the environment throughout the dyeing process and are nonbiodegradable, carcinogenic and mutagenic [3], [4]. As a result, textile azo dyes have certainly gained attention in the field of toxicology, environmental monitoring and assessment.

Polluted aquatic body is being the source of acute or chronic toxicity for aquatic organisms. Fish is one of the known models for aquatic toxicology. The formation of micronuclei (MN) has been reported in fish erythrocytes, as a consequence of exposure to environmental and chemical contaminants of cytotoxic, genotoxic, mutagenic or carcinogenic action [5]. The formation of morphological nuclear alterations (NAs) was also identified in fish erythrocytes. NAs including nuclear buds (NB), fragmented-apoptotic (FA) and bi-nucleated (BN) cells have been used by several authors as possible indicators of genotoxicity [6], [7].

Fish gills, vital part of the body are multifunctional and are the site of direct uptake of toxicants as they constantly exposed to the environment. Histopathological changes in gills directly affect the haematological parameters as well as kidney functioning [8], [9].

The Indian major carp, *Catla catla* is playing an important role in the economy. As it has fastest growth rate, is preferred to culture throughout a year. It is one of the popular edible fish foods. Due to its high sensitivity, economic importance of *Catla catla* and lack of data on toxicity of RR 120, the present study was undertaken to evaluate haematotoxicity and histotoxicity of RR 120 on Indian major carp *Catla catla*.

## II. MATERIALS AND METHODS

### A. Fish Collection and Acclimatization

*C. catla* fingerlings (10±3 cm long; 17±4 g weight) were procured from local government fish farm, Gujarat and were kept in tanks filled with dechlorinated water and given continuous aeration to acclimatize in laboratory conditions for 2 weeks prior to the dye exposure. Necessary physico-chemical parameters of water were measured and maintained according to APHA [10] are enlisted in Table I.

Fingerlings were fed artificial food @ 5% of their body weight once a day. Water along with their excreta was changed daily.

### B. Preparation of Stock Solution and Exposure Details

Azo dye RR 120 (Fig. 1) used in this study was obtained commercially from the local source and was directly used for the experimental purpose.

TABLE I  
PHYSICO-CHEMICAL PARAMETERS OF WATER

No.	Parameter	Measured value
1.	Temperature	25±2°C
2.	pH	8.3±0.2
3.	Hardness (as CaCO <sub>3</sub> )	122-136 (mg.l <sup>-1</sup> )
4.	Alkalinity	118-122 (mg.l <sup>-1</sup> )
5.	Dissolved Oxygen	7.4±0.2 (mg.l <sup>-1</sup> )

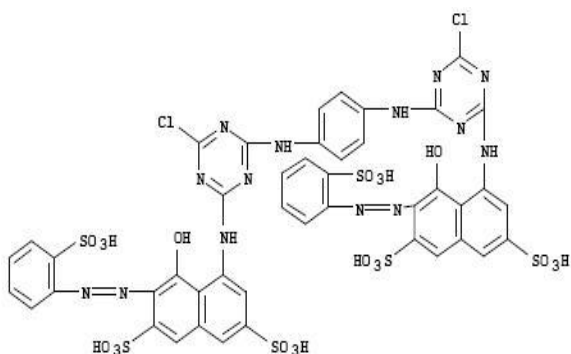


Fig. 1 Chemical structure of C.I. Reactive Red 120

Stock solution was prepared and diluted further to obtain selected concentrations (10, 20, 30, and 40 mg.l<sup>-1</sup>) for the exposure. Hundred fingerlings were sorted irrespective of sex from the acclimatized stock and grouped into nine. First group (n=10) were kept in dye free, dechlorinated tap water as a control. Rest of eight groups (n=10) exposed to above mentioned concentrations of RR 120 in duplicates for 96 h. They were not fed for 24 h before being sacrificed for haematological as well as histological studies.

### C. Haematological and Histopathological Studies

After 96 h from exposure, peripheral blood samples were obtained from the caudal vein of the dye exposed fingerlings as well as control and smears were prepared on clean slides through gills and kidney [11], [12]. The slides were then air dried, fixed in pure methanol for 20 min, and stained with 10% Giemsa solution for 25 min. To determine micronuclei in

targeted cells, the slides were examined using oil-immersion (x 1000).

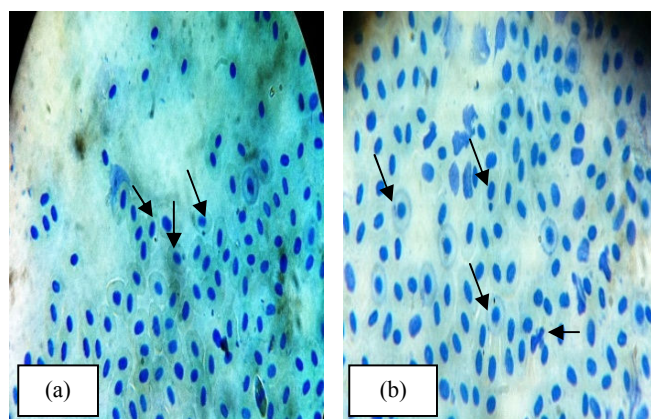
Gills and kidneys were dissected out for the same purpose as well as histopathological study. Some amount of gills and kidneys were transferred to fixative formaldehyde for tissue processing and microtomy [13].

All the haematological and histopathological observations were made using Carl Zeiss Trinocular microscope, Axio scope A1. Microphotographs were taken and documentation was done. These changes were compared with those of the controlled.

## III. RESULT

Fingerlings from control group showed normal morphology as well as nuclear shaped blood smear. Fingerlings exposed to different concentrations of RR 120 showed marked changes both in their blood cells' morphology and in nuclear material as compared to control. Figs. 2 (a) and (b) represent formation of micronuclei (MN), nuclear buds (NB), fragmented-apoptotic cells (FA) and bi-nucleated cells (BN) respectively in blood smears of fingerlings exposed to different concentrations of RR 120. Moreover, the smears prepared from tissue homogenates also showed the similar changes at 96 h after exposure. As all these changes were time and concentration dependent, they showed severity with the increasing concentrations Figs. 2 (c) and (d).

Histopathological sections of gills taken from control group showed normal and precise arrangement of central axis, primary gill filaments, secondary gill lamellae, respiratory epithelium etc. Fingerlings exposed to dye showed severe damage in the gills structure with respect to control. Remarkable changes such as aneurism, hyperplasia, degenerated central axis, lifting of gill epithelium, curved secondary gill lamellae were observed in the gills of dye exposed fingerlings (Figs. 2 (e) and (f)). On the other hand, kidney of exposed fingerlings showed noticeable alterations in their histological structure as compare to control. Histopathological changes like shrunken glomeruli, increased periglomerular space, degenerated renal tubules were observed (Figs. 2 (g) and (h)). Similar to haematological results, these histopathological changes were also time and concentration dependent.



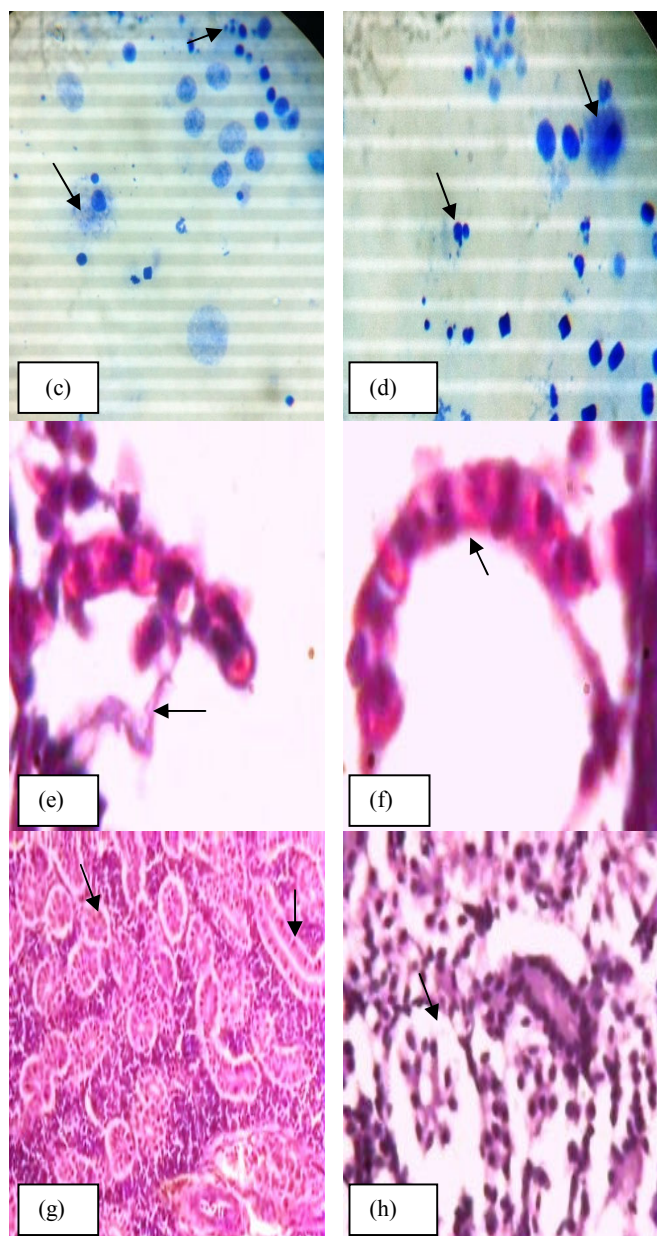


Fig. 2 Microphotographs of smears and histopathological sections showing dye toxicity: (a) arrows indicate MN formation in blood cells; (b) arrows indicate MN, BN and FA in blood cells; (c) arrows indicate MN and FA in gills cells; (d) arrows indicate MN and FA in kidney cells; (e) arrow indicates epithelial lifting from secondary gill lamella; (f) arrow indicates curved secondary gill lamella; (g) arrows indicate normal glomerulus and renal tubule; (h) arrow indicates totally distorted renal tubule with loss of cellularity

#### IV. DISCUSSION

The present study focused on the cytogenotoxicity of RR 120 by measuring micronucleus test. *In vivo* Micronucleus assay is devised primarily for evaluating the potentiality of toxicant to induce structural and/or numerical chromosomal damages in the exposed fingerlings [14]. In this study intoxication of dye for 96 h showed gradual formation of both MN and NAs at different concentrations [15].

Hyperplasia shown by the gills of dye exposed fingerlings

might be one of the responses of immune system to avoid the direct diffusion of any toxicants into the body [16]. On the other hand, epithelial lifting was also a protective response in order to keep the distance between secondary gill lamellae and toxicant which leads to curved secondary gill lamellae [17]. These alterations are somehow being barriers for oxygen uptake as well as blood circulation and purification by gills. Ultimately, they might affect the whole gills structure and functions.

The histopathological changes in the kidney after the exposed to different concentrations of dye might indicate the kidney disfunctioning or failure [18].

Similar histopathological alterations in gills and kidney were also observed in our previous studies in *Labeo rohita* fingerlings exposed to various sublethal concentrations of Direct Green 6 and Acid Orange 7, azo dyes [19], [20]. *Labeo rohita* again showed marked changes when exposed to textile mill effluent for acute and chronic toxicity study [21]. Nile tilapia exhibited same histopathological changes exposed to malachite green [22]. *Gambusia affinis* exposed to textile effluents also showed such marked changes in gills [23]. *Channa punctatus* showed such alterations in gills histopathology on the exposure of paper mill effluent for 96h [24]. These MN formation and histopathological findings were also reported in earlier research work carried out with *Onchorhynchus mykiss* to evaluate the sublethal effects of some synthetic dyes [25].

#### V. CONCLUSION

The present findings conclude that different concentrations of RR 120 induced MN formation, NAs and histopathological changes as well. Looking to the genotoxic and histotoxic potential of dye, one should minimize the release of dye in the environment through precise pre-treatment of wastewater before discharge. This study also suggests checking dye toxicity at chromosomal levels.

#### REFERENCES

- [1] R.Saratale, G. Saratale, J. Chang and S. Govindwar, "Bacterial decolorization and degradation of azo dyes: a review," *J. Taiwan Inst. Chem. Eng.*, vol. 42, pp. 138–157, 2011.
- [2] Y. Verma, "Toxicity assessment of dye containing industrial effluents by acute toxicity test using *Daphnia magna*," *Toxicol. Indus. Health*, vol. 27, pp. 41–49, 2011.
- [3] S. K. Garg and M. Tripathi, "Process parameters for decolorization and biodegradation of orange II (Acid Orange 7) in dye-simulated minimal salt medium and subsequent textile effluent treatment by *Bacillus cereus* (MTCC 9777) RMLAU1," *Environ. Monit. Asses.*, vol. 185, pp. 8909–8923, 2013.
- [4] N. Mathur, P. Bhatnagar and P. Sharma, "Review of the mutagenicity of textile dye products," *Uni. J. Environ. Res. Technol.*, vol. 2, pp. 1-18, 2012.
- [5] K. R. Carrasco, K. L. Tilbury and M. S. Mayers, "Assessment of the piscine micronuclei test as an *in situ* biological indicator of chemical contaminants effects." *Can. J. Fish. Aquat. Sci.*, vol. 47, pp. 2123–2136, 1990.
- [6] F. Ayllon, and E. Garcia-Vazquez, "Induction of micronuclei and other nuclear abnormalities in European minnow *Phoxinus* and mollie *Poecilia latipinna*: an assessment of the fish micronucleus test." *Mutat. Res.*, vol. 467, no. 2, pp. 177-186, 2000.
- [7] T. Da Silva Souza and C. S. Fontanetti, "Micronucleus test and observation of nuclear alterations in erythrocytes of Nile tilapia exposed

- to waters affected by refinery effluent." *Mutat. Res.*, vol. 605, no. 1-2, pp. 87-93, 2006.
- [8] F. A. Vigliano, N. Aleman, M. I. Quiroga and J. M. Nieto, "Ultrastructural characterization of gills in juvenile Argentinian silverside, *Odontesthesbonariensis* (Valenciennes, 1835) (Teleostei: Atheriniformes)." *Anat. Histol. Embryol.*, vol. 35, pp. 76 – 83, 2006.
- [9] S. J. Teh, S. M. Adams and D. E. Hinton, "Histopathologic biomarkers in feral freshwater fish populations exposed to different types of contaminant stress," *Aqua. Toxicol.*, vol. 37, pp. 51-70, 1997
- [10] APHA (2005). Standard methods for the examination of water and waste water, 21<sup>st</sup> Ed. Washington, DC.
- [11] A. Fagr, A. M. El-shehawi and M. A. Seehy, "Micronucleus test in fish genome: A sensitive monitor for aquatic pollution, *African J. Biotechnol.*, vol. 7, pp. 606-612, 2008.
- [12] D. Palhares and C. K. Grisolia, "Comparison between the micronucleus frequencies of kidney and gill erythrocytes in Tilapia fish, following mitomycin C treatment." *Genet. Molec. Biol.*, vol. 25, pp. 281-284, 2002.
- [13] R. J. Roberts, *Fish Pathology*, West Sussex, UK, 4<sup>th</sup> ed. Blackwell Publishing Ltd, 2012, pp. 462.
- [14] W. Zhang, W. Liu, J. Zhang, H. Zhao, Y. Zhang, X. Quan and Y. Jin, "Characterisation of acute toxicity, genotoxicity and oxidative stress posed by textile effluent on zebrafish," *J. Environ. Sci.*, vol. 24, no. 11, pp. 2019–2027, 2012.
- [15] S. Sharma, S. Sharma, P. K. Singh, R. C. Swami and K. P. Sharma, "Exploring fish bioassay of textile dye wastewaters and their selected constituents in terms of mortality and erythrocyte disorders," *Bull. Environ. Contam. Toxicol.*, vol. 83, pp. 29–34, 2009.
- [16] M. C. Wood, "Toxic response of the gills." in *New prospective: toxicology and environment: target organ toxicity in marine and freshwater teleosts*, D. Schlenk and W. H. Benson, Eds. London: Taylor and Francis, 2001, pp. 1, 2001.
- [17] A. K. Srivastava, R. Sinha, N. D. Singh, S. J. Srivastava, "Histopathological changes in a freshwater catfish, *Heteropneustes fossilis* following exposure to malachite green." In *Proc. Indian Nat. Sci. Conf.*, India, 1998, vol. 68 (B), pp. 123–127.
- [18] M. Abdel-Moneim, N. M. AbouSabana, S. E. M. Khadre and H. H. Abdel Kader, "Physiological and histopathological effects in cat fish exposed to dyestuff and chemical wastewater," *Int. J. Zool. Res.*, vol. 4, pp. 189-202, 2008.
- [19] J. Barot and A. Bahadur, "Behavioural and histopathological effects of azodye on kidney and gills of *Labeo rohita* fingerlings," *J. Environ. Biol.*, vol. 34, pp. 147-152, 2013.
- [20] J. Barot and A. Bahadur, "Histotoxicity of Acid Orange 7 on organs of freshwater fish *Labeo rohita*," *Res. Rev. J. Toxicol.*, vol. 1, pp. 1-9, 2011.
- [21] S. B. Nikalje, D. V. Muley and S. M. Angadi, "Histopathological changes in gills of a freshwater major carp *Labeo rohita* after acute and chronic exposure to textile mill effluent (tme)," *Internat. J. Environ. Sci.*, vol. 3, no. 1, pp. 108-118, 2012.
- [22] M. S. El-Neweshy and M. A. AbouSrag, "Chronic malachite green toxicity in Nile tilapia: Pathological and hematological studies with special reference to quantitative histopathological assessment." *Researcher*, vol. 3, no. 4, pp. 55-64, 2011.
- [23] K. P. Sharma, S. Sharma, S. Sharma, P. K. Singh, S. Kumar, R. Grover and P. K. Sharma, "A comparative study on characterization of textile wastewaters (untreated and treated) toxicity by chemical and biological tests," *Chemosphere*, vol. 69, pp. 48-54, 2007.
- [24] R. Kaur and A. Dua, "96 h LC<sub>50</sub>, behavioural alterations and histopathological effects due to wastewater toxicity in a freshwater fish *Channa punctatus*," *Environ. Sci. Pollut. Res.*, vol. 22, pp. 5100-5110, 2015.
- [25] M. J. Marlasca, B. Valles, M. C. Riva and S. Crespo, "Sublethal effects of synthetic dyes on rainbow trout *Oncorhynchus mykiss*: A light and electron microscope study," *Dis. Aquat. Org.*, vol. 12, pp. 103-110, 1992.

Karyomorphology, biochemical studies and biodegradation of them.



**Jagruti Barot**, (Surat, Gujarat, India, 26<sup>th</sup> December, 1984) got her Ph.D. degree in the field of Environmental Toxicology, Sir P. T. Sarvajanik College of Science, Veer Narmad South Gujarat University, Surat, Gujarat, India, December 2011. Major areas of research are toxicological studies of pollutants using various experimental models and biomarkers such as histopathology, haematology,